

1942

# The embryological development and physiology of the endocrine organs of the common fowl (*Gallus domesticus*)

Walter George Venzke  
*Iowa State College*

Follow this and additional works at: <https://lib.dr.iastate.edu/rtd>

 Part of the [Animal Sciences Commons](#), [Cell Biology Commons](#), [Physiology Commons](#), and the [Veterinary Physiology Commons](#)

## Recommended Citation

Venzke, Walter George, "The embryological development and physiology of the endocrine organs of the common fowl (*Gallus domesticus*)" (1942). *Retrospective Theses and Dissertations*. 13591.  
<https://lib.dr.iastate.edu/rtd/13591>

This Dissertation is brought to you for free and open access by the Iowa State University Capstones, Theses and Dissertations at Iowa State University Digital Repository. It has been accepted for inclusion in Retrospective Theses and Dissertations by an authorized administrator of Iowa State University Digital Repository. For more information, please contact [digirep@iastate.edu](mailto:digirep@iastate.edu).

# NOTE TO USERS

This reproduction is the best copy available.

**UMI**<sup>®</sup>



THE EMBRYOLOGICAL DEVELOPMENT AND PHYSIOLOGY OF THE  
ENDOCRINE ORGANS OF THE COMMON FOWL  
(GALLUS DOMESTICUS)

by

Walter George Venzke

A Thesis Submitted to the Graduate Faculty for the  
Degree of

DOCTOR OF PHILOSOPHY

Major Subject: Veterinary Anatomy

Approved:

Signature was redacted for privacy.

In charge of Major work

Signature was redacted for privacy.

Head of Major Department

Signature was redacted for privacy.

Dean of Graduate College

Iowa State College  
1942

UMI Number: DP12279

### INFORMATION TO USERS

The quality of this reproduction is dependent upon the quality of the copy submitted. Broken or indistinct print, colored or poor quality illustrations and photographs, print bleed-through, substandard margins, and improper alignment can adversely affect reproduction.

In the unlikely event that the author did not send a complete manuscript and there are missing pages, these will be noted. Also, if unauthorized copyright material had to be removed, a note will indicate the deletion.

**UMI**<sup>®</sup>

---

UMI Microform DP12279

Copyright 2005 by ProQuest Information and Learning Company.

All rights reserved. This microform edition is protected against unauthorized copying under Title 17, United States Code.

ProQuest Information and Learning Company  
300 North Zeeb Road  
P.O. Box 1346  
Ann Arbor, MI 48106-1346

QL959  
V569e

TABLE OF CONTENTS

|   |     |
|---|-----|
| INTRODUCTION .....                                    | 3   |
| REVIEW OF LITERATURE .....                            | 5   |
| Hypophysis cerebri .....                              | 5   |
| Glandula thyreoides .....                             | 9   |
| Glandula parathyreoides .....                         | 12  |
| Thymus .....  | 14  |
| Glandula suprarenalis .....                           | 17  |
| Indifferent Gonad and Ovarium .....                   | 23  |
| Testis .....  | 31  |
| Growth of the endocrine organs .....                  | 35  |
| EXPERIMENTAL .....                                    | 37  |
| Material and Methods .....                            | 37  |
| Observations .....                                    | 41  |
| Hypophysis cerebri .....                              | 41  |
| Glandula thyreoides .....                             | 53  |
| Glandula parathyreoides .....                         | 61  |
| Thymus .....  | 64  |
| Glandula suprarenalis .....                           | 74  |
| Indifferent Gonads .....                              | 88  |
| Ovarium .....   | 94  |
| Testis .....  | 100 |
| Growth of the Endocrine Organs .....                  | 109 |
| DISCUSSION .....                                      | 125 |
| Hypophysis cerebri .....                              | 125 |
| Glandula thyreoides .....                             | 135 |
| Glandula parathyreoides .....                         | 140 |
| Thymus .....  | 143 |
| Glandula suprarenalis .....                           | 149 |
| Indifferent Gonad and Ovarium .....                   | 153 |
| Testis .....  | 162 |
| Morphological and Functional Interrelationships ..... | 165 |
| SUMMARY AND CONCLUSIONS .....                         | 178 |
| Hypophysis cerebri .....                              | 178 |
| Glandula thyreoides .....                             | 181 |
| Glandula parathyreoides .....                         | 182 |
| Thymus .....  | 183 |
| Glandula suprarenalis .....                           | 184 |
| Indifferent Gonads .....                              | 186 |
| Ovarium .....   | 187 |
| Testis .....  | 188 |
| LITERATURE CITED .....                                | 189 |
| ACKNOWLEDGMENTS .....                                 | 204 |
| PLATES .....  | 205 |

T7404

## INTRODUCTION

Although there have been many papers published on the individual endocrine glands for a part of, or for the complete incubation period, an embryological study of the interrelationship of the developing endocrine glands in Gallus domesticus has never been undertaken.

There is little known at present regarding the exact time in embryological development when the hormones of the various glands become physiologically available for use by the organism. The present study has been made entirely from a morphological basis. Therefore, the results which are presented may serve as a foundation for future investigations in the correlation of morphological and physiological changes which occur in the glands.

Investigations in the field of genetics have been directed recently to studies in phenogenetics in an attempt to determine the inheritance of causes rather than effects. The poultry husbandman is being lead into the study of inheritance of factors influencing the quantity and quality of poultry products. Before variations attributable to inheritance can be studied, it is necessary that some idea of the limits of normal variability be ascertained for use as reference material. With this in mind, data are presented to show the growth rate of the glands and the presence or absence of sex differences in White Leghorn chick embryos during the incubation period. This particular phase of the investigation completes a series of data previously reported by Breneman (16) for chicks from hatching until

thirty days of age, and a similar study for older chickens reported by Latimer (76).

The observations presented in this study, and the compilation of literature included herein, should be a valuable source of reference to anatomists, embryologists and endocrinologists interested in the developing endocrine system of the domestic fowl.



#### REVIEW OF LITERATURE

The literature reviewed for this investigation covers publications on the embryological development, histology, cytology, physiology, and rate of growth, of the hypophysis, thyroid, parathyroid, thymus, and adrenal glands, ovaries and testes of the common fowl (Gallus domesticus). It is evident from this review, that the literature is limited. Many of the papers are concerned with only a part of the embryological period, or with the development of a particular endocrine gland. Some papers cover the entire embryological development of a particular endocrine gland, but the observations have been made at greater intervals than those in the present investigation. In no case were papers found covering a systematic study of all the endocrine glands with an attempt to interpret functional inter-relationship. Little data were available on the weights and rate of growth of the glands from the tenth to twenty-first day of the incubation period.

#### Hypophysis cerebri

The early morphogenesis of the hypophysis cerebri in birds has been very well described. Rathke (114) was the first investigator to recognize that the hypophysis originated as an outpouching of the oral epithelium. Prior to this time von Baer (155) described the hypophysis of older chicks as arising from the infundibulum. These studies were followed by those of Reichert (117) who concluded that the hypophysis developed from the anteri-

or end of the spinal cord, and Dursy (33) who thought that it was formed by both the spinal cord and brain. Müller (96) presented a detailed description showing that Rathke's interpretation of the origin of the hypophysis of the bird was correct. Bruni (18), Atwell and Sitler (8), and Pfeiffer (103) established the fact that the chicken hypophysis is ectodermal in origin.

A well-marked infundibulum arises just posterior to the optic chiasma by the close of the third day of incubation (Lillie) (79). It gives rise ventrally and posteriorly to an infundibular process which, by the sixth day of incubation, appears as a blind sac lying posterior to the pars glandularis according to Rahn (111).

Müller (96) and Economo (34) made their studies on the hypophysis before the pars tuberalis was found to be a distinct structure of the pars glandularis. The pars tuberalis was first recognized in the chick by Tilney (150), and was so named because of its close relation to the tuber cinereum. Atwell and Sitler (8) stated that the pars tuberalis makes its appearance after 59 hours of incubation.

The pars tuberalis has been confused with the pars intermedia by several authors, namely, Lothringer (81), Herring (54), Stendell (140), and Krause (73). The pars intermedia has also been considered absent by Collin (20) and DeBeer (28). DeLawder, Tarr, and Geiling (30) studied the chicken hypophysis because of the "apparent absence of a well-defined pars intermedia either closely investing the pars posterior or invading the neural tissue in the form of strands of epithelial cells, as in the case

of most mammals." Rahn (110) stated that in the region of the pars intermedia the cytology reveals a few cell cords which can be variously interpreted. Rahn (111), from a study of the residual lumen, separation of the pars glandularis and the infundibular process by connective tissue, and the cytology, vascularity and general structure of the juxta-neural region concluded that a typical pars intermedia is absent in the chicken. According to Atwell (7) the hypophysial cavity makes its disappearance following the ninth day of incubation in the chick, and so it is impossible to demonstrate a discrete pars intermedia. Rahn and Painter (112) have more recently concluded that there is no evidence for a definite pars intermedia.

Atwell (7) has shown that on the ninth day of incubation the residual lumen of Rathke's pouch is broken up into an isolated lumen at the extremity nearest the pars nervosa and another, larger lumen near the attachment of the epithelial stalk, as the result of the growth of the hypophysis. Rahn (111) also found that the residual lumen has disappeared except for a small remnant occurring rarely in the cephalic lobe after the ninth day of incubation.

Various workers Economo (34), Tilney (150), Atwell and Sittler (8), Pfeiffer (107), and Lillie (79) have directed their attention to Seessel's pouch. All of these authors have agreed that after the fourth day of incubation it recedes, and plays no further role in development of the hypophysis. At the sixth day of incubation, Atwell and Sittler (8) stated that it remains as a small bud at the base of the hypophysial stalk near the oral

epithelium.

Atwell (7) stated that the hypophysial stalk cavity is discontinuous at seven days of incubation and becomes subdivided during the following four days. Atwell further found that the stalk remains attached to the anterior division of the pars glandularis at least until the sixteenth day of incubation.

According to Atwell (7) the pars nervosa is well formed and contains a large cavity continuous with the third ventricle of the brain by the seventh day of incubation. The distal part of the lobe is attached to the infundibulum by a narrow neural stalk. By the eighteenth day of incubation the pars nervosa is separated from the pars glandularis by a layer of connective tissue.

The pars glandularis in the chick is bilobed; this condition arises about the sixth day according to Rahn (111). Bilobation of the pars glandularis was first observed by Tilney (150), but was not described. Rahn (111) has pointed out that the two lobes are cytologically distinct; the caudal lobe possesses typical basophils, acidophils and chromophobes; the cephalic lobe contains basophils, chromophobes and weakly-staining acidophils which differ in several particulars from the acidophils found in the caudal lobe. Tilney (149) reported a central acidophilic and peripheral basophilic area in the chicken pars glandularis.

The time of cell differentiation during embryonic development has been followed by Rahn (111). Acidophils and basophils appear on the tenth day of incubation, and are preceded by undifferentiated cells which exhibit a

basophilic tendency about the eighth day. The cephalic lobe is the first to contain acidophils. These acidophils greatly increase, and by the eighteenth day are present in the whole pars glandularis and pars tuberalis.

#### Glandula thyroideae

According to the view held by Remak (118), Mall (85), Verdun (154), and Marine (87), the entire thyroid gland of the chick develops from a single median anlage. The age at which the thyroid anlage first appears has been reported by Lillie (79) as 35 hours, by Bradley (15) as 54 hours, by Yoshikawa (174) as 42 hours. The age at which the thyroid anlage loses pharyngeal connection has been observed by Lillie (79), Bradley (15), Yoshikawa (174), to be 96, 120, and 72 hours respectively.

The age at which the thyroid gland becomes completely paired varies; according to Verdun (154) this occurs at 172 hours; according to Lillie (79), at 168 hours, and Bradley (15) and Yoshikawa (174) stated that it occurs at 120 hours.

Bradley (15) stated that at the end of six days of incubation, each thyroid body which had previously been solid begins to form non-follicular spaces; these become obliterated some time later by the ingrowth of non-glandular mesoderm. Yoshikawa (174) stated that this change occurs at five and one-fourth days of incubation.

Bradley (15) reported that at the end of eight days the tissue destined to form follicles takes on the appearance of a labyrinthine system

of tissue. The cells of the follicular walls are columnar in shape and two cells in thickness; before this time there is no definite arrangement of cells. Plates of epithelial cells, separated by circulatory spaces, become distinctly visible between five and one-half and eleven days according to Yoshikawa (174). On the other hand, Sun (142) stated that at six days of incubation the thyroid gland is found to have a cordlike structure.

As reported by Sun (142), the vesicles in the tissue first appear at nine days of incubation in the chick, and the epithelial cells of the vesicles are of a cuboidal type. Bradway (15) stated that at the end of eleven days, primary follicles begin to form. This observation is in good agreement with Yoshikawa (174) who stated that follicles begin to contain colloid at eleven and one-half days. Hopkins (62) found that colloid first appears on the tenth day of incubation.

Bradway (15) stated that at twelve days of incubation the colloid substance in the vesicles shows a chromophilic reaction, by which it is assumed that the thyroids have now begun to function. Yoshikawa (174) also found that the first colloid to appear is chromophilic. Sun (142) has observed that at fifteen days of incubation the thyroid glands appear to be almost the same as those of the adult bird, and that the epithelial cells of the follicles are flattened.

The smaller follicles, according to the findings of Bradway (15), are globular in the eleven to twelve day chick embryos. From the thirteenth to the twenty-first day of incubation, the thyroid follicles become pro-

gressively larger, ovoidal in shape, forming groups of two or three without connective tissue between them.

Bradway (15) found that approximately one-half of the large follicles of the thyroid gland from fifteen to twenty-one days of incubation contain chromophobe colloid; the remaining follicles contain chromophile colloid. Bradway further found that chromophobe and chromophile colloid is secreted at the same time by different cells in the same follicle. Hopkins (62) found that in the chick embryo not only are chromophobe and chromophile colloids present in different cells of the same follicle at the same time, but that both occasionally are present in the same cell at the same time.

Hopkins (62) has observed that growth in size of the thyroid follicle takes place by a fusion of follicles, while the follicles increase in number by proliferation of interfollicular epithelial cells. Bradway (15) found that the follicles become larger by follicular cell proliferation and by addition to the stored colloid. She also stated that "neither growth of follicles by fusion of follicles nor multiplication by budding takes place except in very rare instances."

Hopkins (62) has observed that some follicles, in late developmental stages, have had tubular exits at some time during their functional cycles; these are thought to represent the path by which the chromophile colloid (diluted by the chromophobe) reaches the circulation.

By use of vital staining technique, Hopkins (62) has been able to demonstrate that elements of the reticulo-endothelial system are present in the developing thyroid gland.

Sun (142) made iodine determinations as soon as the vesicles appeared. He found that the iodine content in the glands increases with age of incubation. Sun stated further that the morphological point of view does not exactly agree with chemical determinations as to when the thyroid begins to function. The percentage of active principle of the thyroid reaches a normal level immediately after hatching.

#### Glandula parathyreoideae

Verdun (154) was the first to show that the parathyroids of the bird are entodermal glands. He believed that they are derived from the dorsal part of the third and fourth branchial pouches.

Marine (86) believed that the parathyroids of the fowl are more susceptible to overgrowth than those of mammals.

Nonidez and Goodale (98) have discussed briefly the gross and histological anatomy of the parathyroids and surrounding anatomical structures.

Sun (142) stated that at the eighth day of incubation the parathyroid tissue is cordlike in arrangement. He reported that during the last part of the incubation period the gland becomes very similar in appearance to that of the adult gland; at this time it is cordlike and the cell groups are separated by connective tissue. Because this characteristic cordlike structure remains throughout the incubation period, Sun doubted that the gland has any function in the embryo.

Higgins, Foster, and Sheard (58) discussed briefly the normal histology of the parathyroids of chicks under essentially normal conditions. These



authors mentioned that occasionally in a normal gland one encounters remnants of a persistent duct. These structures are lined by cuboidal or columnar epithelium, and have been interpreted as embryonic rests.

Idiopathic hypoparathyroidism and tetany in fowls has been studied by Hutt and Boyd (63).

Leonard and Righter (78) have studied the gland-weights in bantam fowls. Male birds averaging two hundred and fifty days of age had parathyroids whose average weight was 10 milligrams. Female birds averaging three hundred and sixty three days of age had parathyroids whose average weight was 7.6 milligrams.

Juhn and Mitchell (67) obtained a series of weights of parathyroids in Brown Leghorn hens, cocks and capons. The parathyroids were found to be similar in hens and capons and lighter in the cock.

Higgins and Sheard (57) studied the effects of selective solar irradiation on the parathyroid glands of chicks. Of particular interest was the presence of cysts which accompanied the retrogressive processes that occurred within the gland. One type of cyst was walled off from the remaining portion of the gland by a columnar epithelial layer; another type was enclosed by a series of concentrically arranged flattened cells.

Forsyth (39) has described the thyroid and parathyroid glands of several species of birds. The gross anatomy and histological structure of the parathyroids are briefly discussed. Frequently this author observed thyroid glands which contain varying amounts of parathyroid tissue. In all cases

where both types of structures are present, no line of separation between the two could be found. Parathyroids attached to the posterior pole of the thyroid are often found to be continuous with the thyroid paranchyma. Small accessory glands situated near the thyroid often contain thyroid and parathyroid tissue.

Macowan (84) made observations on the ductless glands, serum calcium, and egg-laying in the fowl. He found that the parathyroid glands show marked changes in size and histological structure. The changes are related to the calcium level in the blood serum and to the size of the egg in the oviduct or ovary. The histological picture of the parathyroid glands is described under the conditions of the experiment.

#### Thymus

Verdun (154) studied the early development of the thymus in the chick and stated that the third clefts are not open to the exterior after 124 hours of incubation. He stated further that their internal and external extremities atrophy early, while the dorsal intermediate portions form an entodermal epithelial pouch against the internal jugular vein on either side of the neck. These pouches then give rise to an epithelial cord on each side of the neck, and extend the full length of the jugular vein, corresponding to thymus III.

Verdun (154) found that the fourth cleft separated from the pharynx at 164 hours of incubation. This cleft was found to give rise, through the dorsal and superior region, to a thymic bud, thymus IV. Verdun reported

that eventually thymus IV terminated by fusion with thymus III.

Lillie (79) concluded that the thymus of the chick embryo has a double origin on each side. The main portion of the thymus, which Lillie called thymus III, was thought to be derived from the dorsal wall of the intermediate part of the third visceral pouch, then elongated to form an epithelial cord along the jugular vein. Lillie believed that a smaller portion, thymus IV, was derived from a corresponding part of the fourth visceral pouch and fused with thymus III. These observations agree with those of Verdun.

A more complete study of the development of the thymus has been made in other bird species. Helgesson (55) has studied the development of the thymus in Passer domesticus up to the 14 millimeter embryo. Hamilton (51) has studied the development of the thymus in Anas boschas up to the 45 millimeter embryo. Most of the work pertaining to the thymus of the chicken is physiological in nature.

Experimental work on the thymus of the chicken showed that both thymectomy and feeding of thymus give contradictory or unsatisfactory results. Tarulli and Lo Monaco (146) thymectomized chickens, and those which survived showed no symptoms. Basch (10) removed the visible thymus from five young chicks and, three months later, found that they had as much thymic tissue as the controls. Soli (136) thymectomized laying hens and found that the eggs laid were normal until seventeen to twenty days after the operation. At this stage, eggs were produced with defective shells for eleven to twenty days, after which time eggs with normal shells were again laid. Achert and

Morris (2) found no constant differences between thymectomized and control fowls when weight of eggs, strength, appearance and thickness of eggshells, calcium carbonate in eggshells, fertility and hatchability of eggs, weights of certain organs and blood hemoglobin were compared.

Morgan and Grierson (94) found that the size of eggs, amount of albumen, and eggshells from thymectomized fowls were entirely normal. Morgan and Grierson (95) also found it difficult to remove the thymus entirely in chickens but were successful in four cases. Maughan (90) observed that thymectomy does not alter the shell or inner structure of the egg. Greenwood and Blyth (49) frequently observed thymic tissue near and posterior to the thyroid. The distribution of the thymic tissue is variable; it is present under the thyroid capsule, penetrating the substance of the thyroid gland, external to the thyroid capsule, but closely apposed, or extending around the posterior lobe of the thyroid and coming to lie between it and the parathyroid glands. Terni (147) and (148) reported "thymus-like tissue" within the substance of the parathyroid glands of the fowl.

Dantschakoff (24) assumed that, in the bird, the reticulum and Hassall's corpuscle are the only elements which develop from the original epithelial anlage. This author was of the opinion that the small thymic cells (or lymphocytes) and eosinophiles are of mesenchymal origin.

Sun (142) stated that prior to fifteen days of incubation the thymus of the chick appears as a group of undifferentiated cell masses held together by mesenchymal tissue. The cortex, medulla, and Hassall's corpuscles do not definitely show until fifteen days of incubation. Sun is of the

opinion that the function of the thymus, as determined from morphology, probably commences after this time.

Naughtan (90) stated that there are, in all, approximately 14 distinct thymic lobes, usually seven on each side of the neck, loosely joined together. No thymic material was found in the thoracic cavity.

Pensa (101) described myoid or sarcolyte cells in the thymus of birds and reptiles. Further, Pensa believed that these cells are embryonic muscle fibers which result by inclusion from the musculature of the branchial clefts.

Latimer (76) found that at first the thymus forms a little less than 0.5 per cent of the net body weight of the single-comb White Leghorn chick. This study of the chicken thymus showed that it increases both in percentage and absolute weight up to sexual maturity, and then undergoes involution. The thymus changes were found to be more closely related to age than to body weight.

Greenwood (46) observed a definite relationship between the gonad and thymus involution in the fowl.

#### Glandula suprarenalis

According to various investigators the cortical substance of the adrenal gland may be derived from several possible sources. The theory of mesonephric origin is supported by Semon (130) and Hoffmann (60). Janosik (64) and (66), Fusari (42), and Loisel (80), found a very intimate

relationship between the adrenals and the gonads, and believed that the cortical portion of the adrenals was derived from the germinal epithelium. Valenti (152) and Soulie (137) supported the theory that the cortical substance of the adrenal glands develops from the peritoneal epithelium. Hays (53) stated that the anlagen which give rise to the cortical substances of the adrenal glands appear as groups of cells which migrate dorsally from the peritoneal epithelium. This worker also found that the vessels of the arterial system are almost entirely in the cortical substance.

Several theories have also been proposed to account for the development of the medullary or "chromaffin substance" of the adrenal glands. Janosik (64) and (66) and Valenti (152) believed that it is derived from the germinal epithelium. Fusari (42), Rabl (109), Minervini (93), Loisel (80), Soulie (137), and Poll (105), believed that the chromaffin substance originates from the sympathetic nervous system. Hays (53) reported that the chromaffin substance is derived from indifferent cells which wander in from the anlagen of the prevertebral sympathetic plexuses. This investigator also found that the chromaffin substance lies in contact with the venous blood vessels.

Willier (167) found a thickening of the coelomic epithelium, known as the adrenal zone or cortical primordium, appearing on the anterior medio-ventral surface of the mesonephros early during the fourth day of incubation. Rau and Johnston (115) found that there are already signs of the grooves in the coelomic epithelium from which the cortical portion of the adrenal

glands will arise in Passer domesticus equivalent to the 78-hour chick. The adrenal glands begin development just posterior to the glomeruli of the pronephros and extend posteriorly where they become continuous with the anterior portion of the germinal epithelium. Willer (1937) stated that during the later portion of the fourth day, nodules of cells proliferate from the adrenal zone into the mesenchyme, lying ventral and lateral to the dorsal aorta. At the end of the fourth day of incubation the cortical nodules are only slightly connected with the coelomic epithelium. By 113 hours of incubation, according to Soulie (1937), the cortical nodules become completely separated from the coelomic epithelium.

Willer (1937) has observed that at 96 hours small groups of cells originating from the sympathetic nervous system are in close contact with the medial surface of the cortical primordium. According to Rau and Johnston (1935), these cells from the primary sympathetic chain eventually form the medullary or chromaffin cells of the adrenal gland.

Most investigators do not agree as to the exact relation of the sympathetic cells to the adrenal cortical nodules. Harris (1932) found sympathetic cells in rather close contact with cortical nodules, but no distinguishable intermingling of cells and nodules. Goormaghtigh (1935) has reported that ganglion cells, but no chromaffin cells, are found between the cortical nodules of a chick embryo incubated four days and 16 hours.

Rabl (1939) observed that the adrenal consists of a group of cortical cords, the cortical primordium, with a group of sympathetic cells located

on the medio-dorsal surface; this condition prevails up to the sixteenth day of incubation. According to Rabl (109) and Scullie (137) this group of sympathetic cells, during the eighth and ninth days of incubation, constitutes the primordium of the medulla. Willier (167) has observed that to the end of the sixth day the medulla is composed largely of cells originating in the primary sympathetic trunks. After this time the primary sympathetic cells are apparently supplemented by cells from the secondary or definitive sympathetic trunks. According to His (59) and Kuntz (74) the secondary sympathetic trunks first appear as series of groups of neuroblasts located just medial to the ventral roots of the spinal nerves. At the same time connections appear at varying intervals between the primary and secondary sympathetic nerve trunks. Abel (1) and Rau and Johnston (115) stated that the primary sympathetic trunk, as such, is incorporated in part in the secondary sympathetic chain of ganglia, and disappears. Willier (167) has observed that by the eighth or ninth day of incubation, the mass of sympathetic cells in contact with the anterior end of the cortical primordium has become rather large. Rabl (109) stated that this mass of sympathetic cells is connected with ganglia of the secondary sympathetic nerve trunks by nerve strands. Sympathetic cells are migrating along these nerve strands to the medullary primordium.

Scullie (137) has observed that from the end of the sixth day of incubation the mass of sympathetic cells in contact with the cortical primordium shows two types of cells: large ganglionic, and small non-ganglionic cells. Rabl (109) stated that these cell types are visible



at least to the sixteenth day of incubation. He regarded the non-ganglionic cells as "embryonic ganglionic cells", while Soulie (137) called them "parasympathetic cells." These cells are most numerous next to the cortical primordium. According to Willier (167) they penetrate between the cortical cords to become the medullary cords. Lillie (79) stated that the non-ganglionic cells possess large vesicular nuclei with granular contents, and that they are "precisely like the specific cells of the ganglion, perhaps a little smaller, and without axones."

The exact time of ingrowth of the cells from the sympathetic nervous system into the adrenal glands varies according to the investigator. Fusari (41), and (42) found that penetration occurred at 96 hours of incubation. According to Soulie (137) small "parasympathetic cells" are found between the cortical cords in a 200-hour embryo. Lillie (79) stated that on the eighth day of incubation strands of sympathetic medullary cells can be traced into the superficial portion of the adrenal, and by the eleventh day the cells have penetrated through one-third of the adrenal gland. According to Rabl (109) penetration is still in progress in a sixteen-day embryo. Goornaghtigh (45) described an ingrowth of chromaffin cells, beginning at six days and 9 hours of incubation; these cells were of sclerotome origin.

Willier (167) has observed that the cortical substance of the adrenal gland first assumes the form of definite cords at about six days of incubation (at 135 hours according to Soulie). At seven days of incubation the individual cords have become larger and closer together, and from the

seventh to the eleventh day the cortical cords increase in number. Soulie (137) found that the cords have anastomosed and are separated by vascular spaces in an embryo incubated eight days and 8 hours. The cords by this time are well developed and cylindrical in form, with radiating cells, and basally located nuclei, according to Willier.

Willier (167) stated that the laterality of the adrenal is determined at an early stage because of differences in the growth capacities of the right and left primordia. The right adrenal is usually smaller than the left. These results are in agreement with Goormaghtigh's (45) findings for the normal cortical primordium, in which the right gland is smaller than the left.

Sauer and Latimer (127) have observed that the adult female chicken has approximately 30 per cent more adrenal cortex, in proportion to its body weight, than the male, even though the gross weight of the glands is about the same in both sexes. The amount of adrenal cortex is much more variable in the female than in the male.

Hays (53) observed that the entire venous system of the adrenal gland is derived from the subcardinal veins; within the adrenal glands, the vessels of the subcardinal system are sinusoidal in character. Hays (53) also found that there is greatest activity in the development of the vascular systems during the period of greatest influx of cells from the anlagen of the prevertebral sympathetic plexuses. Miller (92), working on the development of the postcaval vein in birds, concluded that the veins of the left adrenal develop from the subcardinal vein, and that probably those

of the right gland are of the same origin.

By use of the intestinal strip method, Hogben and Crew (61) have found that the adrenal of chick embryos becomes functional at the sixteenth day of incubation. Several trials at the fourteenth day of incubation gave doubtful results. Lutz and Case (82) extracted, in Ringer's solution, the adrenal glands of forty-two chick embryos at various ages between seven and twelve days of incubation, and determined their mydriatic potency on the enucleated eye of the frog. All negative cases occurred in chicks from seven to ten days of incubation, but positive evidence of an active agent was found as early as the eighth, ninth and tenth day.

#### Indifferent Gonad and Ovarium

The beginning of modern research relative to the origin and products of the sex glands appeared in Waldeyer's (158) famous work "Eierstock und Ei." He was of the opinion that the definitive ova arises from the primordial germ-cells.

Schmiegelow (128) observed large primordial germ-cells in the germinal epithelium of young chick embryos. He saw that the germinal epithelium is limited on its deep surface by a basement membrane. In older embryos he found that anastomosing cords of cells grow down into the subjacent medullary tissue. Primordial germ-cells are contained in these cords and in the stroma between the cords. Schmiegelow believed that the primordial germ-cells in the stroma do not emigrate from the germinal epithelium in the cellular cords, but differentiate from the mesenchyme in situ. He believed that both

of these kinds of primordial germ-cells could give rise to definitive eggs.

Von Mihalkowics (157) first observed, in embryos of Amniotes, two proliferations of the germinal epithelium in the female. This author's opinion differed from that of Schmiegelow in that he believed that the primordial germ-cells of the sexual cords, as well as those seen in the germinal epithelium, are of peritoneal origin.

Authors differ widely in their opinion concerning the origin of the sexual cords in birds. Janosik (65) believed that these cords are ingrowths of the germinal epithelium. Semon (130) and Hoffmann (60) believed that they arise as outgrowths of the capsules of renal corpuscles. Semon states that they may arise from the neck of the Wolffian tubules.

Frenmant (108) studied the evolution of the gonad, and particularly the origin of the primordial germ-cells. In the three-and-one-half day chick embryo, he observed that the genital ridge is covered with the elongated cells of the germinal epithelium. In this germinal epithelium and in the mesenchyme, which lies beneath it and forms most of the genital ridge, he observed large primordial eggs. He did not find mitotic figures among these primordial germ-cells, yet they increased in number; he concluded that they were produced by differentiation of the cells of the germinal epithelium.

Hoffmann (60) showed that the primordial germ-cells are something apart from the elements composing the germinal epithelium and ovarian stroma. He found that primordial germ-cells exist before the appearance of the germinal epithelium and gonad. He also showed that the definitive ova are

in a direct line of descent from the true primordial germ-cells.

The germinal epithelium is differentiated on the fourth day, according to Lillie (79), by its greater thickness and by the absence of a basement membrane from the adjacent peritoneum. The germinal epithelium appears between the base of the mesentery and mesonephros. As the mesonephros grows into the body cavity, the germinal epithelium is drawn to its median surface. It is difficult to determine the antero-posterior extent of the germinal epithelium in the early stages of development. According to Lillie its origin is near the point of origin of the omphalomesenteric arteries and extends over seven or eight somites.

Two kinds of cells are found in the germinal epithelium: the ordinary peritoneal cells and the primitive ova. Lillie (79) described the primitive ova as being typically round, several times as large as the peritoneal cells, possessing a clear cytoplasm, a nucleus, and one or two nucleoli.

Firket (36) and (37) believed that the cytological aspect of mitochondria used by Rubaschkin (123) and Tschaschin (151) is an unreliable criterion of germ-cells; however, he was of the opinion that it is a convenient method for following the development of these cells. He observed in the chick that most of the primary germ-cells, both of the ovary and testis, eventually degenerate, and the majority of definitive ova or spermatozoa are derived from the epithelial tissues of the sex glands. These constitute a second generation of germ-cells, and are called secondary germ-cells. On the other hand, Firket saw no reason why "certain of the primary germ-cells might not produce some of the definitive cells, since it was impossible to dis-

tinguish between primary and secondary cells."

Von Berenberg-Gossler (156), working with birds, reported recognizable germ-cells differentiating from the genital anlage coincident with its development. He believed that large cells, appearing before the gonads developed, are not germ-cells but cells participating in a late formation of mesenchyme.

Fell (35) studied the gonads of eight birds representing various stages in sex-reversal from female to male. This author found germ-cells of the opposite sex proliferating from the peritoneal epithelium of the degenerating ovary. The sex cords gave rise to seminiferous tubules, and functional sperm.

Swift (143), (144) and (145) published three papers describing his researches on the germ-cells of the chick. He observed that the germ-cells arise in a region anterior and antero-lateral to the embryo and at the margin of the area pellucida. These cells are first seen between the entoderm and ectoderm. When the mesoderm appears in this region, these cells enter the tissue and, later, the blood vessels. According to Swift the primordial germ-cells of his observation are identical with the "entodermal wonder-cells" described by Dantschakoff (24). Swift disagreed with the latter in that he observed no degeneration of the cells which, Dantschakoff believed, eliminated all primordial germ-cells so that they did not participate in gonad formation. Swift concluded that practically all primordial germ-cells do persist, and are carried by the blood stream to all parts of the embryo. At the twenty-second to the twenty-ninth somite stage of development, the

primordial germ-cells take up residence in the splanchnic mesoderm and coelomic epithelium. About the sixth or seventh day of incubation the cells pass into the gonad, and the extragerminal tissues arise as proliferated cords from the epithelium.

Mussbaum (100), Hofmann (60), Kiebel and Abraham (68), Rubaschkin (122) and von Berenberg-Gossler (156) have all described the germ-cells in the splanchnopleure of twenty-two to twenty-three somite bird embryos.

Woodger (172) studied the origin of the germ-cells of the fowl by means of their Golgi bodies. It was possible with this technique to distinguish between germ-cells and somatic cells.

Willier (164) identified primordial germ-cells extra-embryonically, and determined whether they were essential for gonadal development. Evidence is presented to show that in the chick no germ-cells develop in the absence of primordial germ-cells. Where the arese pellucidae were isolated from all germ-cells, no gonads developed.

Richards, Hulpien, and Goldsmith (119) investigated the history of germ-cells in a series of chick embryos from the beginning of incubation to one hundred and eighty days after hatching. These authors find that the early development is entirely in accord with that described by Swift (143), (144) and (145).

Goldsmith (46) first saw primordial germ-cells in the embryo during the primitive streak stage at the outer edge of the proemion, anterior and antero-lateral to the head fold. Up to the 35-hour stage of incubation the primordial germ-cells are found only in extra-embryonic tissues. These

findings are in agreement with Dantschokoff (24) and Swift (143). From 33 to 40 hours of incubation the primordial germ-cells are widely distributed throughout the embryo and blood stream. The cells gradually take up residence in the developing germinal epithelium. By the sixth or seventh day sex could be determined accurately. Goldsmith observed that no widespread degeneration occurs among the primordial germ-cells of either sex.

Matsumoto (89) stated that the primordial germ-cells are first found in the posterior portion of the primitive streak and primitive plate in embryos of 10 hours incubation.

The germ-cell content of the blastoderm has been excised by Reagan (116), irradiated with ultraviolet by Benoit (13), and destroyed by an electric cautery by Dantschokoff et al (27). Histological examination of blastoderms so treated and incubated for two or more days showed the complete absence of germ-cells from the gonadal areas.

Willmer (169) isolated portions of chick blastoderms at certain critical stages in the development of the primordial germ-cells. These isolated portions of blastoderms were tested on the chorio-allantoic graft for their power to form a gonad. Regardless of the nature of the isolated piece from the pellucid area the gonad which differentiated is sterile, forming no male-like sex cords, or ovarian cortex.

Lillie (79) stated that the stroma of the indifferent gonad is formed from mesenchyme. Up to the middle of the incubation period the stroma is sparse; it increases as a result of ingrowth of blood-vessels and accompanying connective tissue.



Lillie has also observed that sexual cords appear within the gonad on the fifth day of incubation, and consist of a solid mass of epithelial cells. The cords extend from the germinal epithelium toward the hilus of the gonad, and into the wolffian body, where they enter into rather close connection with the renal corpuscles. The sexual cords in the wolffian body are very irregular in their course and anastomose freely, corresponding to the rete region of the future testis. Strands of these cells pass dorsally, according to Hoffmann (60) from cortical cords of the adrenal glands.

According to Semon (130) the nature of the gonad may be detected on the fifth or sixth day of incubation by the fact that the right ovary is already much smaller than the left. Swift (144) stated that when the chick embryo has developed for six and one-half days, the formation of the sexual cords of first proliferation ceases, and the sex of the embryo can then be definitely determined.

The tenth day of incubation in the development is of interest because it was at this period that d'Hollander (29) began his study of oogenesis in the chick. According to d'Hollander at the tenth day of development the cortical region of the ovary consists of two zones, a superficial indifferent cell or epithelial layer, and a deeper layer of germinative buds, which later becomes the cortical cords.

Willier (166) presented evidence that the gonad, during the morphologically indifferent period of development, is specifically organized

with respect to sex, and also with respect to laterality in the case of female embryos. This specific organization is already fixed in the gonads of four-day embryos, which is the approximate time of origin of the genital ridge.

The origin of asymmetry in the reproductive system of birds has been referred to and studied by various workers. Firket (36), in studies on the organogenesis of the sex glands of the domestic fowl, mentioned the unequal distribution of primordial germ-cells in the four and three-fourths-day embryonic sex glands. Swift (144) observed that at 90 hours of incubation the left gonad is larger than the right. Swift found more germ-cells on the left than on the right side and believed that this occurs because the left gonad, from its first appearance, was larger in size.

Dantschakoff (26) observed that at the 24 to 26 somite stage of development the left gonad seldom contains less than twice, and generally three to five times, as many germ-cells as the right gonad.

Witschi (170) concluded that the asymmetry in the gonads of birds was the result of a "primary, hereditarily fixed deficiency of the right cortical inductor." This deficiency was thought to "express itself in decreased attraction upon the primordial germ-cells, especially during the phase of their redistribution in the early part of the third day."

Testis

Most of the investigators who have studied the question of the origin of the sex cords and definitive spermatogonia in the male since Waldeyer's (158) article, concluded that the definitive male cells arise either from cells of the germinal epithelium or from primordial germ-cells.

Swift (145) stated that the "primordial germ-cells (ureier, keimzellen, gonocytes, ovules males, ovules primordiaux, urgeschlechtszellen, and germ-cells of the various authors) are found among the cells of the germinal epithelium from its very commencement." These cells were observed in the germinal epithelium of the chick and described by Waldeyer (158).

Waldeyer (158), Balfour (9), and Semon (130) believed that the primordial germ-cells arise in situ from the epithelial cells in the germinal epithelium by a process of cellular differentiation. Since this work has been done there has been an increasing belief that the germ-cells arise at some region in the embryo at a distance from the future gonad; they then migrate into the region of the wolffian body at approximately the time of the appearance of the germinal epithelium. Nussbaum (100), Hoffmann (60), Beard (11), Rubaschkin (122), Swift (143), and Goldsmith (46) are of this opinion.

The germ-cell crescent of the blastoderm has been removed by Reagan (116), destroyed with ultraviolet rays by Benoit (13), destroyed with an electric cauterly by Dantschakoff et al (27), and completely removed by Goldsmith (47). Histological examination of the blastoderms so treated,

and incubated for some time, show the gonadal area free of germ-cells.

Willier (166) observed that the gonad, during the indifferent stage of development, is specifically organized with regard to sex. This specific organization is fixed in the four day embryonic gonads. Willier (169), using a grafting technique, isolated pieces of tissue from the pellucid area and observed that the gonad which differentiates is invariably sterile, and consists of male-like sex cords; the ovarian cortex never forms.

Willier (164) grew whole blastoderms (about 19 hours incubation) in chorio-allantoic grafts to determine their capacity to differentiate gonads after the crescentic area of the so-called primordial germ-cells had been excised. No gonads or other trunk organs developed, and only the anterior organs formed. By transplanting whole blastoderms of later stages (3 and 9 somites) Willier (168) was able to obtain a gonad free of germ-cells.

Waldeyer (158) did not believe that germinal epithelium or primordial germ-cells had any role in the histogenesis of the male gonad. He was of the opinion that the sex cords originate in the middle of the mesonephros and that they grow into the stroma under the germinal epithelium. He also believed that the primordial germ-cells degenerate, and that the mesonephric tissue gives rise to the definitive sex elements.

Before the research of Mihalkowics (157), the true sex cords were confused with the rete cords with regard to their origin and function. According to Mihalkowics the rete cords are derived from the mesonephric tubules and the epithelium composing Bowman's capsule. Firket (36), and Swift (144)

presented evidence that the rete cords arise as condensations of mesenchyme between the germinal epithelium and the mesonephros.

Mihalkowics (157) described the true sex cords as arising from the germinal epithelium. He thought that the cells of the germinal epithelium migrate into the subjacent mesenchyme where they group themselves into cords which finally unite with the overlying epithelium. Janosik (65) believed that the sex cords originate as invaginations or processes of the germinal epithelium.

Laulanie (77) expressed the opinion that the primordial gonad is bisexual. He thought that the germinal epithelium is essential in the production of the female elements, and that the male cells are present in the network of cords and develop from the stroma of the gonad. In the germinal epithelium the cortical ovules are thought to be female while the medullary ovules are male. According to this view the embryonic gonad is not indifferent but hermaphroditic.

Semon (130) believed that the sex cords are outgrowths of the capsules of the mesonephros. He described two types of cells in the germinal epithelium: the columnar epithelial cells and the large primordial germ-cells.

Semon also described the stages through which the columnar cells pass in becoming primordial germ-cells. His opinion concerning the primordial germ-cells is similar to that of Waldeyer (156). Semon (130) observed that the sexual cords grow out from the malphigian bodies and reach the germinal epithelium about the sixth day of incubation.

Hoffmann (60) employed approximately a dozen species of birds from which evidence was obtained to show that some, if not all, primordial germ-

cells do not arise in the modified coelomic epithelium.

According to Firket (36) the cords of first proliferation gave rise to the true sexual cords in the male and to medullary cords in the female. The cords of second proliferation, or the cortical cords, occur and appear later in the female only. The medullary cords in the female go partly into the formation of the ovarian stroma, but in general disappear. The cortical cords, or the cords of second proliferation, give rise to the sexual elements and follicular epithelium in the female according to Swift (144).

Hoffmann's (60) work showed that the primordial germ-cells migrate into the germinal epithelium and then pass into the sexual cord, which develops from the germinal epithelium. Here they become spermatogonia and finally, mature sex cells. Semon (130) stated that the peritoneal mesoblastic cell is the cell from which the spermatozoa develop.

Differentiation manifests itself first in the germinal epithelium and sexual cords. Lillie (79) has observed that in the males the germinal epithelium never attains as great a thickness as in the females, the sexual cords are better developed, and the stroma less abundant than in the females. The differentiating characters become decisive between the sixth and eighth days of development.

During the sixth and seventh days of incubation Swift (145) observed that true sexual cords or seminiferous cords arise from the germinal epithelium. Most of the primordial germ-cells within the germinal epithelium

are carried into the seminiferous cord. The sexual cords remain attached to the germinal epithelium for a very short time. The male sex can easily be recognized at the end of the seventh day of incubation by the nearly equal size of the gonads, the thin germinal epithelium following sexual-cord formation, and the presence of few primordial germ-cells in the germinal epithelium. During the eighth and ninth days of development the sexual cords make up most of the volume of the testes. The stroma begins to increase in the eleven-day testis. Prior to the thirteenth day of development the primordial germ-cells in the sexual cords do not divide; at this time, and for the next four days, active division occurs. The primordial germ-cells give rise to spermatogonia. Swift further stated that the interstitial cells appear on the thirteenth day and reach their greatest development during the seventeenth day of development. The interstitial cells are differentiated stroma cells. Lumina appear in the seminiferous cords during the twentieth day of development. The coelomic cells of the germinal epithelium develop into the supporting cells of the seminiferous tubule.

#### Growth of the endocrine organs

Latimer (76) studied the postnatal growth of the thyroid, thymus, adrenals, hypophysis, ovaries and testes in the Single-comb White Leghorn chicken. Juhn and Mitchell (67) published a report on the endocrine weights in adult Brown Leghorns. These workers attempted to determine

sex differences in the weights of the hypophysis, thyroids, parathyroids and adrenals. They also studied the changes occurring in these glands following castration in the male. Sum (142) reported the weights of the thyroid and adrenal glands from the ninth day of incubation to hatching. Landauer and Aberle (75) published data on the hypophysis, thyroid, adrenal, and testis weights of the White Leghorn chicken. Leonard and Righter (76) presented endocrine weights of the adult male and female Bantam. Breneman (16) studied the growth of Single-comb White Leghorn and Rhode Island Red chicks from hatching until thirty days of age. He has recorded the weights of the thyroid, adrenal, pancreas, and gonad, for both cockerels and pullets.



## EXPERIMENTAL

Material and Methods

All embryos and chickens used in this study were of a pure Single-comb White Leghorn stock maintained by the Iowa State College Department of Poultry Husbandry. Throughout the experiment the fertile eggs were obtained from the same group of hens, which had been maintained on the following laying mash:

|   |            |
|---|------------|
| Ground yellow corn.....                       | 100 lbs.   |
| Pulverized whole oats .....                   | 135 lbs.   |
| Ground wheat or standard wheat middlings..... | 50 lbs.    |
| Wheat bran .....                              | 50 lbs.    |
| Alfalfa meal (bright green) .....             | 35 lbs.    |
| Meat and bone meal (50%) .....                | 25 lbs.    |
| Dried milk .....                              | 15 lbs.    |
| Soybean oil meal .....                        | 40 lbs.    |
| Corn gluten meal .....                        | 10 lbs.    |
| Ground oyster shell or high grade limestone.. | 15 lbs.    |
| Bone meal .....                               | 5 lbs.     |
| Fish meal .....                               | 15 lbs.    |
| Salt .....                                    | 5 lbs.     |
| Cod-liver oil .....                           | 1 1/4 pts. |

## Grain Formula

|                             |          |
|-----------------------------|----------|
| Corn (whole, shelled) ..... | 275 lbs. |
| Oats, wheat or barley ..... | 225 lbs. |

Grain and mash were self fed.

All eggs were incubated in an electrically operated Buffalo incubator.

A series of 420 embryos, ranging from twelve hours of incubation to hatching, was used for the morphological studies. The technique used in preparing the glands for this purpose varied for the individual gland.

In the case of the hypophysis the dorsal part of the cranial vault was removed with scissors to allow rapid penetration of the fixative. The cephalic region of the older embryos was later decalcified in a 1% hydrochloric acid-alcohol solution and then trimmed to remove the accessory tissues surrounding the hypophysis. The sella turcica and the connections to the brain tissue were left undisturbed so that the relations of all structures could be studied.

Helly's fluid, Susa's fluid, and Bouin's fluid were used for fixation of the hypophysis. This was followed by the Dioxane technique. All tissues were embedded in Altmann's paraffin mixture and sectioned serially at six microns.

The Koneff (72) adaptation of the Mallory-azan staining method was slightly modified (phospho-molybdic instead of phospho-tungstic acid) and used for cytological study, and differential staining of the cellular elements of the hypophysis.

For each interval, sagittal and transverse serial sections were made and stained with hematoxylin-eosin.

The material for study of the thymus was obtained by serially sectioning the cervico-thoracic region of chick embryos, ranging in age from 96 hours of incubation until hatching, at intervals of approximately twelve hours.

These tissues were fixed in Bouin's or Helly's fluid and cut in Altmann's paraffin mixture at six microns. Those tissues fixed with

Bouin's fluid were stained with hematoxylin and eosin. Those fixed in Helly's fluid were stained with Mayer's hematoxylin and azur-II eosin or Mallory's connective tissue stain.

Helly's fluid, which was the most satisfactory, did not destroy the basophilic character of the cytoplasm of the lymphocytes and showed clearly the red blood corpuscles in the thymic tissue.

The thyroid glands were fixed in Zenker's fluid, Bouin's fluid and Susa's fluid. All tissues were embedded in Altmann's paraffin mixture. The sections were cut at six to eight microns.

The stains most frequently employed were hematoxylin and eosin. For differentiating the connective tissue in the thyroid glands, the Zenker fixed material was stained with Mallory's connective tissue stain. A filar micrometer was used in measuring the follicular diameters and epithelial heights. The follicular diameter was obtained by measuring the distance from basement membrane to basement membrane. To get a random sample of the follicular diameters, all follicles in three representative fields on every third section were measured from both the right and left gland. The number of follicles measured in each gland varied somewhat because of differences in size of the thyroid glands, and variations in the plane of sectioning. However, the number of follicles measured in all cases represented a good random sample. The follicular diameters for both males and females were pooled for each interval studied. The data were evaluated in terms of the mean, standard deviation and coefficient of

variability, for each interval.

The same staining and sectioning technique employed for the study of the thyroid glands was also used for the study of the parathyroid glands.

The adrenal glands were fixed in Helly's fluid and Orth's fluid, and embedded in Altmann's paraffin mixture. All sections were cut at six to eight microns, and stained by the iron-hematoxylin method.

The ovaries and testes in the developing embryos were fixed in Bouin's fluid or Helly's fluid. All tissues were embedded in Altmann's paraffin mixture and sectioned serially at six to eight microns. Several stains were employed to show the various structures of the glands. Hematoxylin and eosin were used as a routine stain. Iron hematoxylin was admirably suited to the display of cytological structure in those tissues fixed with Helly's fluid. Mallory's connective tissue stain was employed after Helly's fluid in order to show the connective tissue elements of the ovaries and testes. The measurements of the gonads were made while they were intact within the embryo.

A series of 240 embryos was used for determining the weights and rate of growth of the endocrine organs. The endocrine organs of ten male and ten female embryos were weighed each 24 hours from the tenth through the twenty-first day of incubation. The embryos, foetal membranes, and yolk sacs were removed from the shell, and wet weighings of the embryos were made. The endocrine organs were then dissected out and their wet weights were immediately recorded.

After the body and organ weights were recorded, the mean and the standard deviation were determined for each sex. The graphs and tables presented show the ratio of gland weight to body weight and sex differences.

#### Observations

Hypophysis cerebri: In the chicken the pars glandularis of the hypophysis arises between 43 and 48 hours of incubation. It first appears as a median tubular invagination of the ectoderm of the ventral surface of the head, immediately anterior to the oral plate (Lillie, 79). The hypophysial pouch at this time opens widely into the oral cavity. (Fig. 1). Atwell and Sittler (8) found that the anterior end of the fore-gut, which later forms Seessel's pouch, extends farther anteriorly than does the hypophysial pouch. These observations have been confirmed.

In the chick embryo after 60 hours of incubation, the hypophysial pouch, or Rathke's pocket, has deepened and dorsally approaches the infundibulum. At this period some embryos may present a small perforation in the oral plate. When Rathke's pocket first begins to develop, part of its wall is formed by this oral plate; when this ruptures there is an apparent shortening of the hypophysis cerebri. At 72 hours the oral plate in all the embryos has ruptured allowing Rathke's pocket to be constructed from the oral cavity.

Seessel's pouch at 72 hours contacts the dorsal wall of Rathke's pocket, and in most cases opens into it. This area of contact is the

ecto-entodermal line of fusion. The rupture of the oral plate makes the entodermal pouch of Sessel continuous with Rathke's pocket. After 96 hours of incubation Seessel's pouch begins to recede and becomes separated from Rathke's pocket. At 120 hours Seessel's pouch is reduced to a solid bud of epithelial cells at the base of the hypophysial stalk near the oral cavity; it disappears completely at approximately 165 hours of incubation.

The transverse diameter of the proximal part of Rathke's pocket at 110 hours is 95 microns, approximately one-half that of the transverse diameter of the hypophysis. This measurement is increased to 150 microns at 120 hours. At 165 hours the cavity of the hypophysis, or the residual lumen of Rathke's pocket, extends from its apex near the pars nervosa to the area of attachment of the hypophysial stalk. This distance is approximately 500 microns. The width of this residual lumen is approximately six microns. At 177 hours the residual lumen is partially broken up by growth of the hypophysis. It is still complete at the extremity nearest the pars nervosa and near the origin of attachment of the hypophysial stalk. Therefore, the residual lumen first disappears in the region of constriction, or at the bending point of the gland (Fig. 3). By 272 hours the cavity has become so much subdivided that only small portions are to be seen. After 426 hours only occasionally can fragmentary remains be identified.

A definite hypophysial stalk is formed after 110 hours of incubation. It is a patent tube which affords communication between the oral cavity and the lumen of the hypophysis. In some cases at 134 hours it has, become

solid, while in others it is still patent. By 177 hours all embryos possess a solid hypophysial stalk. (Fig. 3). After 191 hours the stalk is no longer continuous, but becomes subdivided into clumps of epithelial cells. Few of these epithelial remnants of the stalk are present after 228 hours, although a remnant was observed in one eighteen-day chick embryo.

The lateral lobes of the hypophysis, which are present for the first time at 60 hours, protrude laterally and anteriorly; their long axes lie parallel to the long axis of Rathke's pocket. (Fig. 2). At 72 hours, within each lobe, there is a cavity which communicates freely with Rathke's pocket. The lobes have increased in size so that the transverse diameter of the gland, measured between the lateral extremities of the two lobes, is 200 microns.

After completion of 120 hours of incubation, the distal extremity of the pars glandularis enlarges and becomes constricted from the oral cavity with which it still communicates by a patent hypophysial stalk. The lateral lobes have increased in size so that the transverse diameter of the gland, measured between the lateral extremities of the two lobes, is 300 microns. They are now united by a prominent median ridge. The growth of the lobes is directed laterally and toward the floor of the brain. A slight transverse constriction in the pars glandularis is visible just posterior to the site of origin of the lateral lobes. This constriction divides the pars glandularis into lobes, the anterior and the posterior lobes of the pars glandularis.

After 148 hours the anterior lobe of the pars glandularis lies vertically and at right angles to the posterior lobe of the pars glandularis at the region of increased constriction, which is most pronounced at the middle of the gland. (Fig. 3). Distinct tube-like epithelial processes have formed from the lateral lobes and extend toward the brain floor. These are the tuberal processes, and they protrude from the middle of the distal half of the pars anterior. These epithelial processes or cords are solid and contain no lumina, but the cells of the cords possess many mitotic figures as they extend from the main lumen of the hypophysis. (Fig. 3). In chick embryos that have been incubated for 165 hours, the posterior lobe of the pars glandularis lies parallel with the brain floor, while the anterior lobe is arranged in the direction of the hypophysial stalk. (Fig. 3).

Between 191 and 228 hours the hypophysial stalk becomes subdivided, releasing distal tension on the anterior lobe of the pars glandularis. This allows the anterior lobe to arrange itself in the same general axis as the posterior lobe. The anterior and posterior lobes are now separated by a groove which is distinct on the lateral and ventral surfaces of the pars glandularis. The groove on the ventral surface is occupied by the anastomosing branch between the two internal carotid arteries. The lateral grooves are occupied by the arteries distal to the anastomosis. (Fig. 4).

The pars glandularis at this time consists of simple cell cords which radiate at right angles about the remnants of the residual lumen. These cell cords may branch, and the space between them contains connective tissue and blood vessels. On the basis of mitotic activity, it appears



that growth is occurring at and near the periphery of the pars glandularis.

A rather marked change occurs in the nuclei of the cells of the pars glandularis in that the nuclei and cytoplasm take on a basophilic reaction, especially around the remnants of the residual lumen. This area contains the oldest cells; those cells near the periphery of the gland are young and undifferentiated. Only small amounts of cytoplasm surround the transparent nuclei. The nuclei of the older cells are large and rather irregular in outline; they contain two or three nucleoli which stain acidophilic. For the first time at 206 hours the cells near the remnants of the residual lumen possess accumulations of basophilic colloid. This basophilic differentiation progresses peripherally as the gland becomes older.

After 240 hours of incubation acidophilic cells appear in the anterior lobe. Numerous cells show small acidophilic granules within their cytoplasm. The basophilic cells stain either deeply or lightly. Most of these cells taking a deep stain are located at the periphery of the gland; however, a few are scattered throughout both lobes.

The anterior lobe of the pars glandularis at 260 hours has rotated dorsally to a horizontal position, and is parallel to the floor of the brain. Growth is taking place more rapidly in the anterior than in the posterior lobe, since the cell cords are more closely packed, and the cells more definitely oriented within the cell cords.

At 272 hours the three types of cells found in the hypophysis are easily distinguishable. The acidophils compose most of the anterior lobe

of the pars glandularis. Large groups of basophilic cells are found in the posterior lobe, but a small number of undifferentiated acidophils are also appearing in this lobe near the region of constriction. Many cells are in a transitional stage. The chromophobic cells predominate in the cell cords near the floor of the brain.

The nuclei of the acidophils are larger and stain more deeply than those of the basophils. The nuclei of the chromophobic cells stain lightly. Basophilic colloid is found in the remnants of the residual lumen in the anterior lobe of the pars glandularis, and also in some of the acinar lumina. These acinar lumina are most prevalent in the anterior lobe. (Fig. 5).

At 319 hours of incubation the acidophilic cells in the posterior lobe of the pars glandularis have become completely differentiated. Thus, the wave of acidophilic cell differentiation has spread posteriorly from its origin in the anterior lobe of the pars glandularis. The nuclei of the acidophils stain deeply basophilic, with one or two brilliant acidophilic nucleoli. The cytoplasm of the completely differentiated cells is granular, however all stages of acidophilic granulation may be observed. Well-differentiated basophils are few in number, and are easily recognized by their clear cytoplasm containing basophilic granules. Their nuclei are relatively clear with acidophilic nucleoli. Chromophobes are rarely seen at this time.

From 331 to 375 hours of incubation a peculiar zonation of cells occurs. The postero-central area of the pars glandularis contains a preponderance

of basophils, while the antero-peripheral area of the anterior lobe and postero-peripheral area of the posterior lobe of the pars glandularis contains mostly acidophils. (Fig. 6). This zonation of cell types does not persist after 388 hours.

At 388 hours the acidophils in the pars glandularis present marked changes. Most of their nuclei have become increasingly dense, stain deeply basophilic, and reveal no chromatic detail. Coupled with this stage of pycnosis is an increase in granulation within the cytoplasm. Those few acidophils which do not have pycnotic nuclei possess very few granules within their cytoplasm, and stain weakly. Very few basophils are present, and they are poorly differentiated. The number of chromophobes approximates the number of basophils.

At 412 hours two types of acidophils seem to be distributed throughout the pars glandularis. The first possesses a brilliant red-staining nucleus with a light pink, slightly granular cytoplasm. The second consists of a definite pycnotic nucleus, which stains dark red to bluish-red, and cytoplasm which stains dark red to bluish-red with rather coarse granulation. The latter type of cell is predominant in the anterior lobe, while the first type is found in greatest numbers in the posterior lobe. This cellular picture persists until 450 hours of incubation.

In chick embryos after 450 hours of incubation, histological differences in both lobes of the pars glandularis characterize the gland. Two types of acidophils are present. The first type possesses a nucleus

which stains a very brilliant orange-red, and rather clear cytoplasm which is not very granular. This cell is found only in the region of the median constriction. The second type of cell has a nucleus which stains a dark bluish color, and cytoplasm which is reddish-blue and quite granular. This cell is found throughout the pars glandularis. Well-differentiated basophilic cells are very common in the anterior lobe, and are found near the original attachment of the hypophysial stalk. Chromophobic cells are scattered throughout the gland but are more common in the anterior lobe and pars tuberalis.

The posterior lobe at 462 hours contains many acidophils which are quite large and have assumed a columnar shape. These deeply staining acidophils possess dark acidophilic nuclei and moderately granular, mildly acidophilic cytoplasm. A few poorly differentiated basophils and chromophobes are also present. The cell cords are not as compact as they are in the anterior lobe. The anterior lobe presents a different picture. At its cephalic tip the acidophils have become slightly granular and stain light pink to light yellow. (Fig. 8). Proceeding posteriorly to the region of constriction, the number of light staining cells decreases. Deeply staining acidophils similar to those found in the posterior lobe are also present in the anterior lobe.

In chick embryos after 498 hours of incubation the anterior lobe of the pars glandularis is slightly basophilic under low magnification, and the cell cords are more closely packed than those of the posterior lobe.

Basophils are rather numerous around the original site of attachment of the hypophysial stalk and in the postero-central area. Chromophobes are more numerous than in the posterior lobe.

The cephalic portion of the anterior lobe is composed almost entirely of light staining acidophils. These cells have an affinity for Orange-G, and appear yellowish-red. The cytoplasm is very finely granular. These cells become fewer in number toward the median constriction of the gland. In the anterior lobe, just anterior to the area of constriction, there are large numbers of intensely staining acidophils typical of those found in the posterior lobe. The granular cytoplasm stains brilliantly with azocarmine, and the nuclei of these cells take a basophilic dye. It seems that as the nucleus becomes more basophilic, the cytoplasm becomes more granular.

The posterior lobe is composed almost entirely of the intensely staining, coarsely granular acidophils; a few light staining acidophils and an occasional basophil are present. Chromophobic cells are rare in the posterior lobe. They appear as undifferentiated cells with no affinity for dyes, and with a transparent nucleus.

Tilney (150) first recognized the pars tuberalis in the chick and stated that it arises from the lateral lobes just anterior to the median transverse constriction. The pars tuberalis was first observed at 60 hours of incubation.

The pars tuberalis is represented by two buds with rounded extremities at 166 hours. (Fig. 3). These buds are attached to the pars glandu-

laris just anterior to the transverse constriction which contains the internal carotid arteries and their anastomosing branches. The buds arise from the dorso-posterior surface of the anterior lobe of the pars glandularis. A very small lumen is visible in each tuberal process, but this lumen does not communicate with the hypophysial cavity. The tuberal processes grow dorsally toward the floor of the brain. They lose their lumina at 191 hours.

At 240 hours the pars tuberalis is composed predominantly of light basophilic to chromophobic cells; however, some of its cells stain deeply basophilic. By 252 hours the tuberal processes have almost reached the floor of the brain and are separated from it by connective tissue strands. At 272 hours the tuberal processes are flattened against the brain floor.

By 284 hours the pars tuberalis has become very prominent and its cells are beginning to show signs of definite organization. Viewed from a sagittal section, the whole structure assumes a definite Z-shape on either side of the brain floor. Numerous chromophobes and a few basophil cells compose the structure at this time.

The Z-formation of the pars tuberalis is lost by 307 hours. Occasionally at 331 hours a completely differentiated acidophil cell appears in the pars tuberalis. At 462 hours of development the pars tuberalis has encircled the infundibular process and extends anteriorly as a thin sheet of cells to the optic chiasma. (Fig. 8). The cells of this structure at 498 hours are acidophilic, with an occasional basophil and chromophobe. The acidophils are not very granular; however, they take a medium acido-

philic staining.

The infundibulum is well marked at 96 hours (Fig. 1) and gives rise, ventrally and caudally to an infundibular process. At 134 hours the infundibular process is quite prominent, and is directed posteriorly and ventrally. At 165 hours the infundibular process, which becomes the pars nervosa, is rather wide laterally, and is attached to the infundibulum. (Fig. 3).

The pars nervosa at 177 hours is represented by outpocketings of the infundibular process. A lateral outpocketing is now present on either side of the process. There are four small evaginations on either side of the infundibular process at 272 hours. (Fig. 5). That evagination or outpocketing which is the most anterior shows the widest lumen laterally, while the other evaginations become progressively smaller, thus giving the whole infundibular process a tapered form. After 295 hours of development secondary diverticula appear off of the four main lateral outpocketings. All of these outpocketings and diverticula communicate with the infundibular recess.

At 331 hours of incubation the pars nervosa is well-formed and contains a cavity continuous with the third ventricle of the brain. This cavity, on cross-section through its widest part, now measures 350 microns. The distal part of the lobe is wide (800 microns) from side to side. The pars nervosa is quite irregular in contour because of the formation of the primary and secondary evaginations, and is separated from the pars glandularis by a layer of connective tissue approximately 50 microns in thick-

ness. (Fig. 7).

The nuclei of the cells found in the pars nervosa stain acidophilic, and the entire lobe takes a bluish-red stain.

The pars nervosa continues to grow, and at 498 hours consists of a knob-like thickened extremity containing a narrow cavity which communicates with a narrow infundibular lumen. (Fig. 8). Outpocketings, already described, extend from both sides of this cavity. The thick end of the pars nervosa is enlarged because of direct growth, and because of the surrounding mass of vascular connective tissue which separates it from the pars glandularis. The pars nervosa is composed of a supporting type of cell whose nucleus stains acidophilic and whose cytoplasm is clear and non-granular.

The anterior and posterior lobes of the pars glandularis seem to be partially separated from each other by a connective tissue septum which penetrates from the dorsal surface. This septum arises from the connective tissue sheath surrounding the pars glandularis.

That portion of the pars glandularis which should become the pars intermedia is in intimate contact with the pars nervosa, and is separated from the pars anterior proper by the residual lumen at 165 hours. (Fig. 3). At 191 hours topographical recognition of the pars intermedia is difficult because of the disappearance of Rathke's pocket. However, after 357 hours of incubation, two of the embryos showed actual contact between part of the pars nervosa and the pars glandularis. In the 426-hour chick embryo



the pars glandularis is separated from the pars nervosa by a vascular connective tissue sheath from which many vessels extend into the pars glandularis. (Fig. 7). This, then, excludes the possibility of a pars intermedia.

Glandula thyreoidea: The thyroid glands arise as a spherical evagination of the epithelium of the floor of the pharynx. The evagination occurs between and a little in front of the ventral ends of the second pair of visceral pouches. This evagination first appears from 30 to 36 hours of development, and is represented by a well-defined plate of high columnar cells. The plate becomes well-defined as the incubation period progresses, and at 72 hours of incubation it forms a saucer-shaped depression. (Fig. 9). At 84 hours the plate resembles a well-developed sac with a rather wide mouth, and the thyroid primordium appears as a small spherical vesicle lying beneath the floor of the pharynx. By the fourth day the thyroid sac loses all connection with the pharyngeal epithelium.

The thyroid tissue measures 150 microns through its greatest diameter at 110 hours, and there is a slight groove in the structure both dorsally and ventrally. The nuclei of the cells about the periphery of the cellular mass are larger than those located centrally. Most of the mitotic figures are found near the periphery. A large number of small nuclei are found centrally in the gland. There is a clear protoplasmic zone between the central and peripheral layers of nuclei. (Fig. 10).

At 120 hours the thyroid gland tissue has become bilobed. (Fig. 11). The nuclei of the cells near the periphery are larger than those near the center of each lobe. Most of the mitotic figures are seen in the clean protoplasmic zone described for the 110-hour chick. A slight projection of cells can be seen on each lobe at the point where they finally separated. The two lobes are separated by a distance of 50 microns, and each measures approximately 160 microns through its greatest diameter. A single cell-layer-connective-tissue capsule is present about each lobe. The two lobes are located dorsally and medially to the second aortic arches.

The thyroid lobes at 134 hours consist of two different types of cells. One is a small cell with little cytoplasm, and a dark staining nucleus; the other is large, contains much clear cytoplasm, and possesses a large nucleus with little chromatin material. Mitotic figures are most prevalent among these large clear cells. The average diameter of the two lobes through the greatest diameter is 250 microns.

Clearly-defined non-follicular spaces can be observed at 148 hours. (Fig. 12). Some of these spaces are spheroidal, others are irregular in shape. These spaces do not communicate with each other, but they indicate the beginning of the process of coalescence.

In the 165-hour chick the non-glandular mesenchyme invades the non-follicular spaces from the surface of the gland. As a result of this mesenchymal invasion, the thyroid cells are grouped into cords. (Figs. 13,

14).

The ultimobranchial bodies at 177 hours are located ventral to the jugular veins, in contact with the thyroid glands. At 206 hours the ultimobranchial bodies are partially surrounded by the thyroid glands.

Prior to 191 hours the thyroid cells have had no special arrangement. At this time the coiled cellular cords of the thyroid are composed of a double thickness of clearly-outlined columnar cells.

At 213 hours the thyroid gland has increased to 300 microns, measured through the greatest diameter. (Fig. 14).

At 228 hours practically all of the non-follicular spaces contain blood elements. These spaces are enlarging in size, and they show more coalescence. The cytoplasm of the thyroid cells is increasing and is very sensitive to hematoxylin dye. The nuclei stain lightly with hematoxylin-eosin. The ultimobranchial body is in close apposition to, but remains apart from, the thyroid.

At 240 hours the thyroid tissue which later forms follicles, continues to break up. (Fig. 15). The rearrangement of cells into spherule formation is in progress, the nuclei of the thyroid cells stain with varying density. The large nuclei stain lightly with hematoxylin, and the small nuclei stain densely. A few cells contain globules of chromophobic colloid. (Figs. 15, 16).

Nuclei of the thyroid cells at 252 hours are uniform in size, stain lightly, and possess very little chromatic material. All of the nuclei possess one or two nucleoli. The number of cells containing chromophobic

colloid globules is increasing.

An occasional primary follicle is noted in the thyroid tissue at 260 hours of development, and prefollicular globules are rather abundant. These globules are composed of chromophobic colloid. The follicular cells are cuboidal in shape with the nuclei peripherally located. The cells which contain the chromophobic colloid possess nuclei which are slightly bean-shaped. The colloid is located near the bean-shaped nucleus on the side next to the lumen of the follicle to be formed. The cell outlines are indistinct, and the glandular tissue has a syncytial appearance. It is difficult to ascertain whether these droplets of colloid first appear intracellularly or intercellularly. The fact that colloid is found next to the nucleus would suggest that it first appears intracellularly. The primary follicular cavities are formed by secretion and coalescence of the chromophobic colloid which has its origin near the nucleus on the side next to the lumen of the follicle. Most of the follicles at this time are composed of from six to seven cells.

At 272 hours there are from two to four follicles per section which contain chromophobic colloid. (Fig. 16). The nuclei of some of the cells are elongated. The cytoplasm of the cells is slightly acidophilic.

At 284 hours the thyroid tissue has become very compact, and non-follicular spaces have decreased. This may be caused by the increase in glandular cells, following excessive mitotic activity. The colloid in the follicles stains chromophobic to chromophilic.

Follicles typical of those found in the adult thyroid are observed for the first time at 295 hours. (Fig. 18). The large follicles contain chromophilic colloid, and this colloid may, in turn, contain chromophobic colloid droplets. The follicles vary in diameter from 9 to 16 microns, (Table 1), measured from basement membrane to basement membrane. Most of the follicles are made up of from six to ten cells. The smaller follicles contain chromophobic colloid. Occasionally it seems that some cells in a follicle are secreting chromophobic colloid, while others secrete chromophilic colloid.

The thyroid gland at 307 hours shows many follicles whose diameters range from 11 to 16 microns. (Table 1). At 319 hours the follicles have a diameter of from 12 to 14 microns, and the largest follicles do not measure more than 20 microns in diameter. (Fig. 58). The glandular cells are of two types, those which take a deep eosin stain, and others which stain very lightly with eosin. Those cells which are entering into follicular formation stain deeply and possess small deeply basophilic nuclei. The lightly staining cells, which possess very large, rather clean nuclei, do not enter into follicular formation. Most of the mitotic activity is occurring among the lightly staining cells. These cells are to be inter-follicular cells.

The follicles in the thyroid at 352 hours are more numerous and, as a whole, have increased slightly in size. The largest follicles do not exceed 25 microns, and there are many between 15 and 20 microns. (Table 1).

Most of the follicles contain both types of colloid. Many follicular cells present chromophobe colloid in their cytoplasm next to the nucleus on the side toward the follicular lumen. Vascular spaces surround part of every follicle. In some cases thymic tissue bounds the lateral surface of the thyroid glands.

At 375 hours the largest follicle measured 30 microns in diameter. (Fig. 19). Growth of the follicles is achieved by a fusion of the follicular epithelium with cells which have not yet organized into follicular formation. An increase in the number of follicles is accomplished by follicular formation among the epithelial cords. Nearly all the follicles contain chromophobic colloid droplets. The follicles are all in contact with the vascular spaces. Tube-like openings occur in the follicular wall.

The thyroid follicles at 400 hours average 19 microns in diameter. (Fig. 21). The largest follicle measured 30 microns in diameter. (Fig. 58). The average follicular epithelial height is 8 microns. The type of colloid which the follicle contains is not correlated with size. Chromophobic and chromophilic colloids are found in follicles of all sizes, however, the follicles which contain only chromophobic colloid are usually about 15 microns or less in diameter.

The mean follicular diameter at 438 hours is 22.6 microns, and the mean follicular cell height is 8 microns. (Table 1). Many single tube-like openings proceed from the lumina of follicles to the surrounding

circulatory spaces. (Fig. 21, 22). The basement membrane remains intact, and colloid does not pass out of these openings. Cells which are undergoing mitotic changes are present among the cells of the follicular epithelium.

The mean follicular diameter at 450 hours is 23 microns. (Fig. 58). The cytoplasm of the follicular epithelial cells is markedly granular. The interfollicular cells are slightly larger than the follicular cells. Their nuclei stain lightly basophilic and the cytoplasm is rather clear, and without granules. The gland is very compact, and has crowded many of the vascular spaces out of existence. The endothelial lining of these spaces remains between the follicles, forming a basement membrane for the follicular cells. The largest vascular spaces are found at the periphery of the gland. Many of these spaces still contain erythrocytes.

The connective tissue capsule surrounding the gland is increasing in thickness, and is sending fine trabeculae into the parenchyma.

The mean follicular diameter at 474 hours is 23 microns, (Table 1), and the mean follicular cell height is 7 microns. (Fig. 25). Droplets of chromophobic colloid are present in many of the follicles, giving the colloid a vacuolated appearance.

The mean follicular diameter at 498 hours is 21 microns, and the mean follicular epithelial height is 6.5 microns. (Fig. 58). The glands are very compact, reducing the size of the remaining vascular spaces. The interfollicular cells are larger than the follicular epithelial cells;

Table 1.

Means and Standard Deviations of the Thyroid Follicular  
Diameters of Male and Female Chick Embryos

| Number of embryos | Age in hours | Mean follicular diameter | $\sigma$ (Micra) |
|-------------------|--------------|--------------------------|------------------|
| 10                | 295          | 12.0                     | 1.9              |
| 10                | 307          | 13.6                     | 3.5              |
| 10                | 319          | 14.0                     | 2.5              |
| 10                | 331          | 13.0                     | 2.4              |
| 10                | 345          | 13.3                     | 2.0              |
| 10                | 357          | 16.3                     | 3.7              |
| 10                | 375          | 17.6                     | 3.1              |
| 10                | 388          | 18.3                     | 3.2              |
| 10                | 400          | 19.0                     | 2.5              |
| 10                | 412          | 20.0                     | 2.5              |
| 10                | 426          | 21.0                     | 4.7              |
| 10                | 438          | 22.6                     | 4.8              |
| 10                | 450          | 23.0                     | 4.3              |
| 10                | 462          | 21.0                     | 3.8              |
| 10                | 474          | 23.0                     | 4.1              |
| 10                | 498          | 21.0                     | 2.7              |



they range between 8 and 9 microns in diameter. Follicles containing only chromophobic colloid, and those containing chromophilic colloid and large droplets of chromophobic colloid, are still present.

Glandula parathyreoides: On the postero-lateral surface of each thyroid lobe, at 148 hours, a small group of cells seems to be separating from the main lobe by an invasion of connective tissue fibers. (Fig. 12). These cells, after detachment from the thyroid primordium, become the parathyroid primordium.

At 165 hours the parathyroid primordia have become completely detached, and have migrated 75 microns posteriorly from the thyroid lobes. From these primordia another group of cells are detached by invading connective tissue. This latter group of cells develops into the small posterior parathyroid lobe, while the former develops into the large anterior parathyroid lobe. (Fig. 13).

The anterior lobe of the parathyroid at 213 hours is crescent-shaped, and is surrounded by undifferentiated mesenchymal cells. The smaller posterior lobe is located 50 microns posterior to the anterior lobe. The posterior lobe is a small mass of cells which takes a very deep basophilic stain with haematoxylin. (Fig. 14).

At 228 hours the anterior lobe shows an increase in size. It is semicircular in shape, and gives off branches of cell cords. Mesenchyme, containing capillaries, can be seen between the branching cords of cells. The glandular tissue can not be distinguished from that of the thyroid gland.

The posterior lobe consists of several small branching cell cords, but no blood vessels are present in the mesenchyme between the cords.

The cell cords at 240 hours continue to increase in size and they vary considerably in shape. The cell cytoplasm is less, the nuclei are smaller and stain more basophilic than those cells of the thyroid at this period.

At 252 and 260 hours of development the cell cords show much mitotic activity and are more closely grouped. The vascular supply has increased in the surrounding mesenchyme.

The cell cords are closely packed at 272 and 284 hours. The mesenchyme surrounding the cords has become compressed within the lobes. The cell nuclei are round to oval in shape, and the cytoplasm is distinctly acidophilic in reaction. (Fig. 17).

The lobes at 307 hours are composed of closely-packed convoluted epithelial cell cords. The cytoplasm of many of the cells contains what seems to be a chromophobic colloid, located near the nucleus. These cells appear similar to those of the thyroid just before definite follicular formation has occurred.

At 319 hours two types of cells, differentiated on the basis of staining, appear in the parathyroid lobes. One contains a small highly chromatic nucleus, and cytoplasm which stains deeply acidophilic. The second type stains very lightly with eosin and possesses a large, poorly chromatic nucleus. These cell types apparently result from the previously described cytological activity.

At 375 and 388 hours the large, clear, light-staining cells have decreased in number. These cells possess a non-granular cytoplasm and a pale, vesicular nucleus. The predominant cell type, as previously stated, stains deeply with eosin. These cells now possess a finely granular cytoplasm. The large blood vessels supplying the lobes are harbored in the connective tissue between the epithelial cell cords. (Fig. 20).

Three types of cells can be recognized in the parenchyma at 400 hours. One is the clear cell which has been described above, and which occurs in limited numbers. A second stains lightly acidophilic, is finely granular, and possesses a nucleus which is smaller and less vesicular than that of the clear cell. A third cell type occurs singly or in groups and contains large amounts of granular cytoplasm which stains intensely with acid dyes. The nucleus, however, is much smaller than in the other cell types, and stains deeply basophilic.

The three cell types are present at 412 and 438 hours; the clear cells and deeply acidophilic cells show marked increases in number during this period.

At 450 hours clear cells are rarely present. (Fig. 23). A few granular, deeply acidophilic cells are located near the periphery of the gland, the second cell type is, however, present in greatest numbers. Fine connective tissue trabeculae are penetrating the parenchyma from the glandular capsule.

At 462 hours a few clear cells are present, either singly or in groups. The deeply acidophilic cells show an increase in number, and occur singly

or in groups throughout the entire parenchyma. The finely granular, slightly acidophilic cells are the most numerous. Little difference now exists in size between the three cell types.

At 474 and 498 hours the glandular tissue is extremely compact, reducing the size of the sinusoidal capillaries. The cell cords are two cells in thickness. Both lobes are in close proximity, and the reticular fibers of one lobe extend into the other. (Fig. 24).

Thymus: The greatest development of the visceral arches occurs between 96 and 110 hours of development. The second visceral arch, which is the largest, overlaps both the first and third. All of the arches are wedge-shaped. The fourth visceral arch is small and incomplete ventrally.

By the end of the fourth day the third visceral pouch has formed a small, round, dorsal cleft and a long, ventral, fissure-like cleft. These close at approximately 120 hours. The fourth visceral pouch connects with ectoderm at its dorsal end at approximately 96 hours, but no cleft develops.

At 120 hours of development the second, third, and fourth visceral pouches continue to retain their connections with the corresponding ectodermal grooves. As a result, the visceral pouches and ectodermal furrows are drawn into rather long epithelial tubes as growth continues. This arrangement causes the original closing plate to become deeply invaginated.

It is now possible to observe the double origin of the thymus. (Fig. 26). The large portion, or thymus III, is derived from the ventral and lateral wall of the third visceral pouch. This mass of epithelial cells

elongates to form an epithelial cord extending along the jugular vein. Thymus IV, a smaller portion than thymus III, is derived from the dorsal wall of the intermediate part of the fourth visceral pouch, and fuses with thymus III. The floor of the fourth visceral pouch develops a postero-ventral evagination at 120 hours; this eventually becomes the ultimobranchial body. The dorsal aspect of the third visceral pouch disappears.

The third and fourth visceral pouches sever their connections with the pharynx at 134 hours and remain as patches of epithelium in the mesenchyme of the neck, adjacent to the jugular vein. The ventral portion of the epithelium from the third pouch has fused with the dorsal portion from the fourth to form a thymus body on each side of the neck.

By 134 hours of incubation the ultimobranchial body is completely separated from the main part of the fourth pouch.

The thymus at 165 hours is an epithelial structure. It has the form of an elongated mass of protoplasm and is syncytial in nature. Rather deeply stained, finely-branching protoplasmic threads give the syncytium a distinct reticular appearance.

The majority of the nuclei are ellipsoidal in shape, some are irregular in outline, while others are spherical. A very definite nuclear membrane is present. Some of the nuclei contain one nucleolus while others contain two or three nucleoli.

The mesenchyme closely invests the thymus and, in places, cytoplasmic processes of the mesenchymal cells appear to fuse with the cytoplasm of the

epithelial cells. Large lymphocytes are found scattered throughout the mesenchyme, and local accumulations appear near large blood vessels. (Fig. 27). The lymphocytes are characterized by a basophilic, nongranular cytoplasm and a large highly chromatic nucleus. No lymphocytes have yet appeared in the thymic tissue.

At 177 hours the thymic tissue shows an increase in amount and occasionally a large lymphocyte migrating into its periphery from the surrounding mesenchyme.

At 191 hours the thymic tissue is a solid mass of cells extending dorsally and slightly laterally along the jugular veins. As the posterior third of the cervical region is approached, the thymic tissue migrates dorsally across the jugular veins to the medial side. At 206 hours the thymic tissue shows an increase in large lymphocytes and has migrated posteriorly into contact with the thyroid glands.

At 213 hours irregular lobules appear as a result of growth of the epithelial cells. Lobule formation begins near the head and disappears in the mid-cervical and thoracic regions. The largest number of lymphocytes are found in the tissue nearest the head. The surrounding mesenchyme also shows an increase in lymphocyte content. The thymic epithelial cells are characterized by relatively light staining cytoplasm and large, round to oval, sparsely chromatic nuclei. Blood vessels have not invaded the thymic tissue.

At 228 hours in the mid-cervical and thoracic regions, the thymic tissue has become lobulated and more lymphocytes have appeared. Four to five mitotic figures per field are present among the epithelial cells. The lympho-

cytes located in the mesenchyme surrounding the thymus are of both the large and small type. The small lymphocytes are characterized by a rather small, heavily chromatic nucleus, surrounded by a thin layer of cytoplasm. These cells first appear in the thymus tissue at 240 hours.

Lobule formation continues at 252 hours, but is poorly developed in the thoracic region. A layer of mesenchymal cells closely invests the outer surface of the lobes, forming a limiting membrane for the outer surface of the thymus. Blood vessels are numerous in the interlobular septa, but have not invaded the lobules.

Many large lymphocytes are found throughout the thymic tissue. The small lymphocytes or small thymic cells are more numerous than in the previous periods. Mitoses of both the large lymphocytes and epithelial cells are frequent. Interlobular connective tissue contains numerous lymphocytes.

At 260 hours the periphery of the thymus in some portions shows an epithelial syncytium. Occasionally a vessel of a capillary nature can be found in the thymic lobules.

The number of lymphocytes is markedly reduced within the thymus at 272 and 284 hours. (Fig. 28). Epithelial cells continue to increase near the periphery, but they predominate the entire field. The epithelial or reticular cells are highly variable in shape and size. These cells are so closely packed in most of the tissue that it is difficult to distinctly make out the cell outlines.

At 295 hours the blood supply to the thymus has increased noticeably. Again rather large numbers of lymphocytes of various sizes are appearing in

the thymic tissue, especially around blood vessels within the tissue, and in the interlobular connective tissue. The small thymic cells or small lymphocytes are rather prominent, and are scattered throughout the glandular tissue. These cells contain small round nuclei, stain densely and are surrounded by scanty amounts of cytoplasm which stains faintly basic.

The tissue within the central part of the gland lobules is loosely arranged, while the periphery is rather compact. The vascular supply is greatest in the central portion of the lobule, where fewer lymphocytes are present, and where cells are mostly large epithelial cells similar to those found early in the thymic tissue. The striking thing about these reticular cells is that they have an extremely large nucleus, one nucleolus, and almost no chromatin.

The thymic lobules at 319 hours possess well developed cortical and medullary zones, but these two zones can not be distinctly separated from one another. (Fig. 29). The medulla has formed directly from the epithelial syncytium, whose cells have hypertrophied. The nuclei are large and relatively clear when compared with those of the cortex. The cytoplasm of the syncytium has increased in amount. The cytoplasmic processes of the medulla appear to be continuous with those of the cortex. The epithelial cells in the medulla occur singly or in groups of two or three. These groups of cells are perhaps the beginning of Hassall's corpuscles, since their nuclei are markedly enlarged.

All types of lymphocytes are found in the cortex and scattered in the meshes of the reticulum of the medulla. The reticulum of the cortex is



also formed from the cytoplasmic syncytium of the epithelial cells.

The thymic septa at 345 hours are more compact, although in some areas a very loose structure is maintained. The interlobular septa contain rather large interlobular vessels. The cortex contains a large number of thymic cells entrapped within the meshes of the epithelial reticulum.

The medulla contains many lymphocytes, which make it difficult to sharply distinguish the cortex. Hassall's corpuscles are still in the process of formation. The reticulum of the medulla is much coarser than that of the cortex, and the medulla is not as closely packed with cells as the cortex. It contains most of the blood vessels, but a few small capillary-like vessels are present in parts of the cortex.

The distinctness of the cortical and medullary zones of the thymic lobules can be beautifully demonstrated at 357 hours. Very few lymphocytes remain in the medulla. Small thymic cells are the predominating type in the cortex, but intermediate and large lymphocytes are present. The reticulum is much finer in both the cortex and medulla. The vascularity of the cortical zone is increasing, however, most large vessels are harbored in the interlobular connective tissue.

At 375 hours the lobules of the thymus are closely packed, and the cortex is increasing in thickness. (Fig. 30). Small lymphocytes are by far the most numerous, yet large ones are still plentiful in all parts of the cortex.

The medulla contains less lymphocytes than the cortex. Where the medulla of the lobules joins the central stem, it contacts the deep portion

of the interlobular septa. The strands of the reticulum in the medulla are much coarser than those of the cortex, and its epithelial nuclei are larger, clearer, and more completely surrounded by cytoplasm.

The interlobular connective tissue septa are decreasing in thickness; those lodging the larger blood vessel are still very wide. Fibers of the septa often dip into the cortex of the lobules. Small blood vessels are found throughout the septa and often enter the cortex. Few lymphocytes appear in the septa.

The thymus cortex shows a marked thickening at 388 hours. This excessive cortical growth produces closely-packed lobules and narrowing of the interlobular septa.

One specimen at 388 hours exhibited a portion of the thymus and ultimobranchial body within the thyroid tissue. The ultimobranchial body does not change into thyroid tissue, nor does it develop follicles characteristic of the thyroid gland.

At 400 hours eosinophile cells appear in the thymus in appreciable numbers. The interlobular septa contain numerous lymphocytes, red blood cells and eosinophile cells, both singly and in groups. The largest number of eosinophile cells is found in the medulla. Those in the cortex are widely scattered and usually occur singly. The number of eosinophiles appears to be evenly divided throughout the various aggregations of thymic tissue. (Fig. 31).

At 412 hours most of the thymic lobules contain groups of erythrocytes, of which the largest numbers occur nearest the head. Erythrocytes are dis-

tributed in both the cortical and medullary zones.

By 426 hours many different cell types have appeared in the thymus. Perhaps at this time it would be well to present a detailed description of the thymus. The connective tissue ingrowths from the primitive capsule produce the primary lobules. These ingrowths of connective tissue represent the beginning of thymus stroma. The lobules are widely separated by loose cellular connective tissue, but as the rate of growth of the thymus increase, the lobules become closer, and at the present time the stroma is compressed into thin septa. The stroma, in addition to connective tissue cells, contains lymphocytes in small numbers, reticular cells, an occasional eosinophile cell, and the large blood vessels.

The small thymic cells at present are found closely aggregated in the cortex. The few which are found in the medulla lie in the meshwork of the reticulum.

The original epithelial cells of the thymus, or the reticular cells, are variable in size and shape, and are two or three times the size of the small thymic cells. Their outlines are indefinite. The protoplasm is drawn out into irregular prolongations which anastomose with similar processes from other reticular cells, producing a syncytium. Mitotic activity is common among these cells. The reticular cells are most easily demonstrated in the medulla. Occasionally some of these cells in the medulla become markedly hypertrophied, and include groups of three or four cells. These groups have the appearance of Hassall's corpuscles, and may contain degenerate small thymic cells.

At 426 hours few eosinophile cells occur in the thymus. An occasional eosinophile is found in the interlobular stroma around the vessels in the cortical and medullary portions of the lobule. Some occur in the medulla where it is in direct contact with the interlobular septa, at the point where the lobular veins emerge.

Many erythroblasts are present in the thymus at 426 hours. These cells are characterized by a faint brick-red cytoplasm and a very granular nucleus, and are found singly and in groups.

A large space is occasionally found within the central part of that portion of the thymus nearest the thyroid. These spaces are lined with a simple squamous epithelium. When traced through serial sections, these spaces end blindly, or as a solid epithelial nest, and usually appear to be continuous with the reticulum.

At 438 hours there is a marked increase in eosinophiles and hypertrophied reticular cells in the medulla.

At 450 hours of incubation the connective tissue capsule surrounding each lobe of the thymus has become well-developed. Thin connective tissue septa, which have become compressed by the growth of the parenchyma, are detached from the capsule. These interlobular septa do not penetrate the gland substance except for the thin connective tissue sheaths accompanying the small blood vessels.

The cortex is composed almost entirely of small thymic cells. Wide variations exist in the staining intensity and in the shape and size of the nuclei. The cytoplasm is scanty and stains faintly with hematoxylin

or other basic dyes. These cells lie in the meshwork of the fine reticulum. A few large lymphocytes are found in the cortex, especially along the interlobular septa.

There are a few reticular cells in the cortex, but these are overshadowed by the small thymic cells. These reticular cells are from 8 to 12 microns in diameter. A multinucleated giant cell is occasionally found in the cortex.

Very few eosinophile cells are found in the cortex at this time. They are present in the interlobular stroma, and around blood vessels. Most of the eosinophiles are polymorphonuclear.

At 450 hours the medulla consists predominantly of reticular cells many of which are smaller than those found in the cortex. The thymic cells are much less numerous, so that the outlines of the reticular cells can be followed more easily.

The medulla also contains the bodies of Hassall. These structures are round, acidophilic in nature, and from 30 to 40 microns in diameter. They are composed of concentrically arranged cells, most of which show evidences of degeneration. Reticular cells are connected at the periphery of each Hassall's body.

The medulla is more vascular than the cortex, and a few flat, connective tissue cells surround each vessel.

At 462 hours many mitotic divisions are occurring, especially at the junction of the medullary and cortical portions. The cortex and medulla are densely packed with cells. Eosinophiles have increased, especially in the

medulla, and Hassall's corpuscles have decreased.

The thymus remains unchanged, except for growth, at 474 and 498 hours. (Fig. 32). One embryo was observed in which thymic tissue surrounded most of the anterior lobe of the parathyroid. Another embryo was studied in which the thyroid was completely surrounded by thymic tissue.

Glandula suprarenalis: The cortical primordia of the adrenal glands make their appearance for the first time at varying times between 90 and 96 hours of incubation. These cells appear as a thickening of the coelomic epithelium, dorsal to the open hind gut, ventral and medial to the anterior pole of the mesonephros, ventral and somewhat lateral to the subcardinal veins, ventral to the aorta and medial to the anterior end of the germinal ridge. As these cells develop they become larger and more rounded in shape than the small flat coelomic or peritoneal cells from which they are derived. The nuclei of the cortical cells also differ from those of the parent peritoneal epithelial cells in that they stain less deeply because of the scanty amount of chromatin material. The cytoplasm of the cortical cells also stains less deeply than that of the peritoneal cells.

Mitotic figures are seen in many of the cell nuclei. As a result of this marked mitotic activity the cortical cells at 110 hours of development have increased greatly in number. The cortical cells have been pushed dorsally and grouped into a solid body on either side of the base of the mesentery, slightly medial and ventral to the anterior pole of the mesonephros. This moderate change in position of the cortical tissue is the

result of the increased rate of growth of the mesonephros, body wall, and mesentery. From the solid mass of cells lying on the peritoneal epithelium, a chain of cells can be traced dorsally toward the ventral level of the aorta. These cells lie in the mesenchyme between the mesonephros and the aorta. Many also migrate laterally to the subcardinal vein, surrounding it ventrally and medially. The character of the cortical cells has not changed in regard to their staining properties.

On each side of the dorsal surface of the aorta there is a cord of nerve cells known as the primary sympathetic nerve trunk. This trunk shows a slight ganglionic enlargement opposite each spinal ganglion.

At 120 hours of development the cortical cells have become detached from the peritoneal mesothelium and have migrated dorsally. (Fig. 35). They appear as scattered groups of cells extending from the dorsal surface of the subcardinal veins dorsally to a level midway along the lateral wall of the aorta. Approximately the same level is reached on both sides of the aorta. This locates the cortical cell groups scattered through the mesenchyme between the medial side of the mesonephros and the aorta. Almost the entire region has been invaded by the migrating cortical cell groups. The posterior limits of the developing cortical tissue lies at a point where the subcardinal veins anastomose in the median plane ventral to the dorsal aorta.

There are a few scattered erythrocytes scattered throughout the cortical cells. There is no connection between the cortical cells and the subcardinal veins; however, the vein does push dorsally for a short distance

into the cortical cells at several points.

At this time small branches pass into the cortical tissue from the anterior mesonephric arteries.

At 120 hours of incubation, large oval cells are observed migrating ventrally from the primary sympathetic trunks on either side of the dorsal aorta. These were present in very small numbers in the 110 hour embryo. They usually migrate singly, but occasionally they are found in pairs. As these sympathetic cells approach the loose cortical cell groups, they migrate between the cortical tissue and the dorsal aorta. At this time there is no intimate association of the two kinds of cells. The sympathetic cells are characterized by their large size and deep staining.

From 120 to 134 hours of development there has been a noticeable increase in the amount of cortical tissue. The cortical cells are no longer scattered throughout the mesenchyme between the aorta and the mesonephros, but have become aggregated into large groups of cells. These large, solid groups of cells lie dorso-medially to the subcardinal veins, and ventral to the mesonephric arteries which usually cross over the anterior extremities of the cell groups.

At 134 hours of development, some of the cells migrating from the primary sympathetic trunks enter the cortical tissue, or attach themselves to the surface of cortical cell groups. Some of the sympathetic cells have migrated deeply into the cortical primordium, since the cells of the cortical tissue are not compact.



After 148 hours of development, the cortical cells have become closely grouped into an ovoid mass on each side of the dorsal aorta. The cell nuclei are beginning to stain more deeply because of increased granulation of the cytoplasm. The cell outlines are quite irregular.

Small strands of mesenchymal tissue are found between groups of cells. The adrenal is separated from the mesonephros by a thin layer of flattened mesenchymal cells. The venous circulation is increasing.

Sympathetic cells continue to invade the cortical tissue. There is a group of sympathetic cells on the dorso-medial surface of the anterior pole of each gland. This mass of sympathetic cells in contact with the gland shows two kinds of cells: large ganglionic and small non-ganglionic cells. The non-ganglionic cells are more numerous next to the periphery of the gland. However, at this time both types of cells are migrating into the gland. These cells arise from the secondary or definitive sympathetic trunks. Prior to this time the sympathetic cells were derived from cells originating in the primary sympathetic nerve trunks.

The ganglionic cells are identified by their large size, irregular outline, large nucleus, and amount of cytoplasm. The non-ganglionic cells are smaller, round in outline, and possess a small nucleus and little cytoplasm.

After 165 hours of development, the mass of cortical tissue has increased. (Fig. 34). The cells are arranging themselves in chains, and sinusoids are appearing between them. The nuclei of the cortical cells contain more chromatin material than previously, and they stain more deeply.

Mitotic figures are present in large numbers. The mesonephros has increased considerably in size, and has pushed ventrally into the abdominal cavity. As a result, the adrenal gland contacts the mesonephros only on its dorso-medial surface. Connective tissue fibers are gathering around the gland and will eventually form a tissue capsule. A few of these fibers extend into the parenchyma between the cells from the surface of the gland.

The glands have increased in size to the point that they lie ventrally and medially to the posterior cardinal veins. A branch enters this vessel from each gland, and leaves the gland on its dorso-lateral surface. Blood appears in the sinusoidal spaces between the cell cords.

An artery is given off by each of the anterior mesonephric arteries. These arteries travel anteriorly, one along the lateral border of each gland. They give off two branches to each gland, one near the posterior, and one near the anterior poles of the gland. These then branch on the surface of the gland, and finally enter it as several small branches. Another small artery extends directly from the aorta to the posterior pole of the left adrenal. This artery branches on the surface of the gland, and enters the parenchyma. These arterial branches continue to divide into capillaries within the parenchyma.

The sympathetic cells at 165 hours are showing slight differential changes. It is now difficult to distinguish them from the cortical cells. However, with the iron hematoxylin staining method, the sympathetic cells take a deeper blue color than the cortical cells. The nuclei of the sympathetic cells have become more granular, whereas previously they were quite

clear. The invading cells have a slight tendency to arrange themselves in cords, although many individual cells are present. The mesenchyme surrounding the gland contains large numbers of these cells, indicating an increase in the migration of cells from the sympathetic trunks. The cells enter the glands from all surfaces.

The adrenal glands, after 177 hours, have about the same cross-sectional diameter as the dorsal aorta, approximately 150 microns. More connective tissue is penetrating the cortical cells. Development of the venous sinusoids continues steadily, and the arterial capillary network is becoming more complex within the parenchyma.

At 177 hours the mesenchyme surrounding the adrenal glands is packed with cells from the sympathetic trunks. These cells are entering the gland on all sides, but especially on its dorsal and medial surfaces. This apparently is the peak of migration of cells from the sympathetic trunks.

After 191 hours the adrenal glands are approximately 250 microns in diameter through the center, and 1.5 mm. in length. There is an increase in the number of chromaffin cells which are arranged within the adrenal parenchyma in cords. Large numbers of them are grouped around venous vessels, and some are scattered individually throughout the cortical cells.

At 206 hours the adrenal glands have increased in size, more venous spaces have appeared between the cell cords, and the gland in general is more vascular. The cell cords are becoming more compact, so that it is difficult to see cellular outlines. The cortical cell cords have taken on the appearance of a syncytium.

Three types of cells comprise the medullary substance of the glands. The chromaffin cells, easily distinguished by their darker staining, possess fine, dark staining granules in their cytoplasm. These cells are grouped, in some cases, while in other cases, they form strands. They are closely apposed to the cortical cell cords; in some instances, they form an intimate part of them. The most common cell is the small non-ganglionic type, migrating in from the ganglionic mass along the dorso-medial surface of the gland. These cells migrate into the gland with nerve fibers. The large ganglion cells are confined primarily to the periphery of the adrenal; occasionally one is found deep in the gland. The non-ganglionic cells occur in groups, while the ganglionic cells occur singly in intimate association with the non-ganglionic cells.

After 213 hours, the cortical cells are arranged in cords without distinct cellular outlines. This gives the cell cords a syncytial appearance. Mitotic figures are frequently observed.

The chromaffin cells are more closely grouped, and they arrange themselves around venous blood vessels. At this time the chromaffin cells and the small non-ganglionic cells are about equally divided in the glands; large ganglionic cells are rare, and are confined to the periphery of the glands. The ganglionic masses along the dorso-medial surface of the glands contain all three types of cells, chromaffin, non-ganglionic, and ganglionic. Chromaffin and non-ganglionic cells are usually found together in groups; ganglionic cells are found with a group of non-ganglionic cells.

The connective tissue capsule surrounding the adrenal is developing very slowly, and fine connective tissue fibers are found only between the cortical cell cords.

The venous sinusoids are increasing greatly in size, but the number of sinusoids remains about the same. The sinusoidal walls are made up of a single cell layer of endothelium. The posterior cardinal vein connection with the sinusoids has disappeared.

The diameter of each gland, at 228 hours, is approximately 300 microns; the length, 1.75 mm. (Fig. 35). Fewer mitotic figures are present in the cell nuclei; this indicates a decrease in the rate of growth. Most of the gland is composed of cortical tissue. Venous vessels are surrounded, on at least one surface, by chromaffin cells whose tissue seems to have no regular arrangement. Chromaffin and non-ganglionic cells are about equally divided in the gland, with a slight preponderance of the non-ganglionic type. All three types of cells are found in the ganglionic masses along the glands.

The left adrenal is covered by the left ovary except for a small portion of its most anterior pole. (Fig. 37). The two glands are separated from each other by connective tissue, blood vessels, nerves, and ganglia.

The venous sinusoids still open into the subcardinal veins in many places. No definite vessels carry the blood from the sinusoids to the subcardinal veins. The arterial supply has not changed.

There is a noticeable increase in the size and extent of the venous sinusoids at 240 hours of development. The glandular substance is irregularly spaced by venous sinusoids which form a network throughout the entire

gland. The cortical cells are arranged in the most irregular cords, and form the foundation for the chromaffin tissue. Blood vessels and sinusoids pass between the cell cords.

The chromaffin tissue has no regular arrangement. Two or three cells may be found in a group, or again, they may appear in chains of fifteen or twenty cells, which always border on a sinusoid.

The ganglionic masses consist of equal numbers of chromaffin and non-ganglionic cells. Only rarely is a large ganglionic cell found in the gland, then singly and surrounded by non-ganglionic and chromaffin cells.

The thickness of the tissue capsule, and the amount of connective tissue entering the gland from the capsule, are both increasing. These connective fibers are very fine, and they pass between the cords of cortical cells.

The sinusoids of both glands converge into two groups at the posterior pole of the adrenal, and enter the subcardinal vein by two distinct vessels.

The adrenal glands after 252 hours of development have increased in size so that they completely occupy the space between the anterior pole of the kidney and aorta on the right and left side. The adrenal glands are so closely attached to the kidney that the two structures appear to be continuous. In reality they are separated by at least a mesothelial layer. Sympathetic ganglionic masses, which have been situated on the dorso-medial surface of the adrenal since 191 hours, are found between the aorta and adrenal. They are gradually increasing in size.

The chromaffin cells of the adrenal are becoming very granular, and their nuclei are vesicular, as compared with the more granular nuclei of

the cortical cells. The positive chrome reaction, which these cells have recently acquired, differentiates them from the surrounding ganglionic cells. However, occasionally a large ganglion cell is found, deep in the parenchyma, which does not take this stain. Non-ganglionic cells are less prevalent than chromaffin cells in the gland. The ganglionic masses contain all three types of cells, with the non-ganglionic predominating.

After 260 hours the cortical cell outlines are more distinct. The chromaffin cells are more granular, and are producing a more positive chrome reaction. Sympathetic nerve fibers penetrate the glandular tissue. The ganglionic masses are composed of all three types of cells, but contain very few ganglionic cells. The chromaffin cells predominate in the ganglionic masses, and also within the glands. Occasionally a ganglionic cell will be found surrounded by chromaffin and non-ganglionic cells.

At 272 hours the cortical cell cytoplasm shows more granulation. Ganglionic cells extend from the periphery into the gland between the cords of cortical cells. (Fig. 36). Occasionally an isolated ganglionic cell is present in the parenchyma together with non-ganglionic cells. The ganglionic masses are composed of three types of cells with the non-ganglionic cells predominating. More large ganglionic cells are found in the glands. The non-ganglionic cells are more numerous than the chromaffin cells. The connective tissue fibers between the cortical cells are increasing in number, and the connective tissue capsule is thickening.

After 284 hours the adrenal glands are increasing more rapidly in diameter than in length. They now measure 1.5 mm. in length, and 0.4 mm.

in diameter. The connective tissue capsule has increased to 5 microns.

The cortical cells of the adrenal glands, after 295 hours of development, have rather distinct outlines and granular cytoplasm. They vary in shape from round to hexagonal.

The outlines of the chromaffin cells are not distinct; some are elongated, while others are almost round. The granulation of the cytoplasm in these cells is very marked, causing the cells to take a definite chromoreaction. They still arrange themselves about venous blood vessels, and at least a part of each cell group is in direct contact with at least one of these blood vessels. Non-ganglionic cells are less numerous, and large ganglionic cells are rarely found in the glands.

At 307 hours the two veins carrying the venous blood from the adrenals to the subcardinal veins are completely surrounded by chromaffin and ganglion cells.

Growth of the glands is the only change which has occurred between 307 and 331 hours of development. From time to time chromaffin cell cords have been found to be more abundant in some regions of the gland than in others. A case has again been encountered at this period. The chromaffin tissue appears to be most common about the surface of the glands, in the form of rather large localized areas. These collections of chromaffin tissue are usually present at the anterior dorsal pole, or on the side of the gland. These are also the positions of the masses of sympathetic cells described above.



After 331 hours the ovary of the chick is in very close proximity to the adrenal; the two glands are separated by a thin band of plethoric connective tissue. (Fig. 37). After 357 hours the glands measure approximately 0.6 mm. in diameter and 1.5 mm. in length.

At 388 hours the adrenal glands are more compact, and the venous sinusoids are less voluminous. The cytoplasm of the cortical cells is very dense and granular, and seems to have reached a peak in granulation. Migration of non-ganglionic and ganglionic cells from the ganglionic masses with sympathetic fibers and blood vessels continues. The ganglionic cells within the glands are usually surrounded by non-ganglionic and chromaffin cells.

To some degree the chromaffin cells resemble the non-ganglionic cells. Their nuclei are approximately the same size and structure, however, the chromaffin cells possess more highly granular cytoplasm. The non-ganglionic cells are more numerous than ganglionic cells within the gland.

The arterial capillaries are becoming very pronounced because of a slight increase in connective tissue within their walls. The number of arterial capillaries increases with age of the embryo.

After 400 hours the chromaffin tissue is better developed than at any previous stage. (Fig. 38). Histologically the cortical and chromaffin cell cords are differentiated by their structure and staining reaction. The bulk of the gland consists of a network of cortical cords, with chromaffin cords and blood vessels lying between them. Generally the central portion of the adrenal is distinctly sinusoidal in character, while the

surrounding periphery is quite compact.

Migration of the sympathetic cells from the ganglionic masses does not occur at this time. Masses of ganglionic, non-ganglionic or both cell types together are found contiguous with the surface of the adrenals. These two cell types usually appear together in irregular groups of variable size. Either cell type may be the more common in the group. The sympathetic nerve fibers are becoming extensively distributed throughout the adrenal substance.

At 438 hours many of the glands studied show the chromaffin tissue confined to the periphery. The large veins leaving the gland are completely surrounded by chromaffin tissue. The ganglionic masses contiguous with the surface of the gland contain all three types of cells but a preponderance of chromaffin cells are present. Very few ganglionic or non-ganglionic cells are found in the adrenal substance.

The connective tissue capsule is increasing about the glands and between the cortical cords. At 450 hours the adrenal capsule varies in thickness from 10 to 25 microns.

At 474 hours there occurs an increased migration of non-ganglionic and ganglionic cells from the ganglionic masses into the adrenal substance. Those cords or aggregates of chromaffin cells near the periphery of the glands are now surrounded by a connective tissue network. Fifteen to twenty cells or perhaps just two or three cells may be surrounded by connective tissue. It appeared previously that the chromaffin cells are in intimate contact with the cortical cells. The chromaffin cell cords are now separated from the cortical cords by fine connective tissue fibers and

mesothelial cells lining the sinusoids.

At 498 hours contiguous with the surface of the adrenals are ganglionic masses. Some of the masses are composed of three types of cells; ganglionic, non-ganglionic and chromaffin. Either the chromaffin or non-ganglionic cells predominate in these masses. There are masses composed entirely of ganglionic cells, but are small in size and few in number.

From these masses sympathetic nerve fibers are seen penetrating deeply into the gland substance. Along their course are found all three types of cells. Chromaffin and non-ganglionic cells are the most common along the course of these nerve fibers.

A rather dense connective tissue capsule surrounds the glands. From the capsule fine connective tissue fibers are detached between the cords of parenchymatous cells.

Much of the chromaffin tissue is confined to cords of cells near the periphery of the glands. These cords are separated from each other by fine connective tissue fibers and mesothelial cells. Between these cords there is a fine network of capillaries and small sinusoids. The chromaffin tissue is, however, distributed throughout the glands and some portion of the chromaffin cell cord is always in contact with venous sinusoid.

The cortical cords are irregularly distributed throughout the gland and are separated from one another and from the chromaffin cords by fine connective tissue fibers.

The central portion of the glands is highly excavated by the venous sinusoids. These sinusoids are very small near the periphery of the glands.

Indifferent Gonads: From 16 to 24 hours of development the primordial germ-cells make their appearance. These cells continue to form and to accumulate at their site of origin in the space between the ectoderm and entoderm. With the appearance and growth of the mesoderm the primordial germ-cells must enter this germ layer. Much of the vascular system has started to develop in the mesoderm, thus distributing the germ-cells to all parts of the vascular area and embryo. The germ-cells remain distributed until some time between the 40 and 45 hour stage of development, at which time they disappear from the vascular system. It is during this period that the primordial germ-cells enter the splanchnic mesoderm of the gonadal ridge.

Between 90 and 96 hours the urogenital ridge appears on the medial surface of the wolffian body. This period marks the beginning of the indifferent stage in the development of the gonads, since the urogenital ridge is similar in all embryos, whether they are destined to become male or female. The anterior half of the wolffian body contains the sexual elements which will become the gonads. Just posterior to the gonad there is a non-sexual region of the wolffian body. Posterior to the entire wolffian body the urogenital ridge is found to contain only the wolffian and mullerian ducts.

At 96 hours of development the urogenital ridge is attached to the medial surface of the wolffian body, and between that organ and the base of the mesentery. At this early stage it is difficult to determine the

antero-posterior extent of the germinal epithelium. It seems to begin at some point near the origin of the omphalomesenteric arteries and extends posteriorly for a distance of eight semites. The ridge consists of a single layer of thickened peritoneal epithelium (commonly called the germinal epithelium) and some underlying mesenchymal connective tissue. The germinal epithelium is composed of two kinds of cells, the ordinary peritoneal cells, and the primordial germ-cells. The primordial germ-cells are round, and larger than the peritoneal cells. The germ-cells at this time have a diameter of from 8 to 10 microns; the diameter of the peritoneal cells is from 4 to 5 microns. The cytoplasm is clear in the germ-cells, and the nucleus contains one to two nucleoli. These cells are sharply distinguishable from the peritoneal cells.

The unequal distribution of the germ-cells in favor of the left side is now definitely established. Prior to this time the germ-cells were rather evenly distributed between the right and left gonad. Of 3085 germ-cells counted from four embryos, 919 were present in the right gonad, and 2166 were found in the left. These germ-cells present in the mesentery and the splanchnopleure of the right and left side were not counted.

At 110 hours of development the germinal epithelium has increased in thickness to from three to five cell layers. At the same time, the underlying mesenchyme has also increased.

After 120 hours the germinal ridges or indifferent gonads have increased in size. Their length varies from 1.5 mm. to 2 mm. and their

Table 2.

The Number and Distribution of the Primordial Germ-  
Cells in the 96 Hour Chicken Embryo

| Number of embryos | Total germ cells counted | Right gonad | Left gonad | Percentage of cells in left gonad |            |
|-------------------|--------------------------|-------------|------------|-----------------------------------|------------|
|                   |                          |             |            | Right gonad                       | Left gonad |
| 1                 | 700                      | 181         | 519        | 74.14                             |            |
| 1                 | 626                      | 149         | 476        | 76.16                             |            |
| 1                 | 908                      | 304         | 604        | 66.52                             |            |
| 1                 | 852                      | 285         | 567        | 66.55                             |            |
| Total             | 3085                     | 919         | 2166       | 70.21                             |            |

thickness is approximately 0.50 mm. for the left, and 0.30 for the right.

(Fig. 40). Growth of the wolffian body into the abdominal cavity has crowded the indifferent gonads toward the base of the mesentery. The gonads now rest on the ventral medial surface of the mesonephros in the space between the mesonephros and the mesentery. However, at this time much of the indifferent gonads rests on the walls of the subcardinal veins, from which small branches penetrate the mesenchyme underlying the germinal epithelium. The gonad begins at the anterior pole of the mesonephros, and extends posteriorly for almost two-thirds of its length.

An epithelium, three to five cell layers in thickness, extends for some distance over the root of the mesentery and on to the free surface of each genital anlagen. This germinal epithelium is composed of tall columnar cells supported by a distinct basement membrane. The germinal epithelial cells located near the basement membrane have elongated nuclei; those on the free surface possess round nuclei. All nuclei stain deeply.

The germinal epithelium over the left gonad measures from 25 to 30 microns, as compared to from 10 to 15 microns for that covering the right gonad.

The gonadal mesenchyme or stroma, which lies beneath the germinal epithelium, is increasing rapidly. This embryonic mesenchyme is continuous with the mesenchyme of the mesonephros and the root of the mesentery. The cells of this tissue are closely packed as compared to those found in the mesonephros and the developing mesentery. Their nuclei stain faintly, and their cytoplasm is drawn into processes which anastomose with the processes of neighboring cells. The stroma is more loosely arranged near its attachment to the subcardinal vein and mesonephros, and is dense next to the germinal epithelial basement membrane.

The stroma, which composes a greater part of the gonads, is more voluminous in the left than in the right gonad. Occasionally a narrow cord extends obliquely toward the medial surface of the mesonephros. This cord is characterized by a condensation of mesenchymal tissue, and is known as the cord of urogenital union.

The primordial germ-cells do not as yet form a continuous tissue. They are still found as isolated cells or in groups of two or three in the germinal epithelium; some may be found in the root of the mesentery. These cells are easily identified by their large nuclei, and clear cytoplasm. They measure from 10 to 12 microns in diameter.

At 134 hours of development a marked change is observed in the gonads. The sexual cords have now appeared. These cords, which will become the seminiferous cords in the male and the medullary cords or cords of the

first proliferation in the female, occur as buds or protrusions of cells from the germinal epithelium into the underlying mesenchyme or gonadal stroma. These cords of first proliferation cells push the germinal epithelial membrane ahead of them into the stroma, thus giving the basement membrane an undulating appearance. The basement membrane is still continuous around the germinal epithelium. An occasional primordial germ-cell is found in the buds.

The rete or urogenital cords are better developed, and connect the sexual cords with certain Malpighian corpuscles in the mesonephros.

After 148 hours the production of sexual cords reaches its peak. (Fig. 41). Many mitotic figures are seen in the nuclei of the cells in the germinal epithelium. Much of the gonad is composed of cords of cells, which lie close together and are separated from one another by a few stroma cells. Some of the cords are no longer attached to the germinal epithelium. A definite basement membrane surrounds each cord of sexual cells. The right gonad is 1.5 mm. in length, and 0.80 mm. in diameter; the left is 1.65 mm. in length and 1.00 mm. in diameter. The diameters appear to be increasing, and the lengths decreasing. The arrangement of the cords is definite and characteristic in that they are straight, and extend from the germinal epithelium toward the mesonephros. The largest number of primordial germ-cells is found in the germinal epithelium; many are found in the sexual cords; and finally, an occasional one is found in the stroma between the cords. The rete cords are firmly attached to the Malpighian corpuscles.



At 165 hours the formation of cords of first proliferation has ceased, and morphological sexual differences may now be observed. In those individuals which are destined to become males, the germinal epithelium has been reduced to a single layer of flat to cuboidal cells. The germinal epithelium covering the left gonad in the female consists of three to five cell layers. (Fig. 42). These cells are somewhat taller than those in the male. The cords are still attached to the germinal epithelium in the male, but are becoming detached in the female gonad.

As many as eight or ten primordial germ-cells may be found in one field in the germinal epithelium covering the left female gonad. Occasionally a primordial germ-cell is found in the germinal epithelium of the male gonad; the majority of these cells have gone into the sexual cords. (Fig. 43).

Marked differences in the relative sizes of the gonads have become apparent.

After 177 hours the sex of the individual can be easily ascertained, either microscopically or macroscopically. The germinal epithelium covering the left ovary of the female is three to five cell layers in thickness, and the cell outlines are difficult to see. The number of cell layers present is based on the cell nuclei which stain distinctly. The basement membrane, which previously was continuous around the growing sexual cords, becomes discontinuous at this time. Mesenchymal cells between the cords, cords of cells derived from the germinal epithelium, and primordial germ-

cells are found in the tissue beneath the germinal epithelium. That region beneath the germinal epithelium will now be designated as the medullary region. Continued growth of this region is indicated by the presence of many mitotic figures.

The primordial germ-cells are more evenly distributed in the germinal epithelium of the left female gonad, but a large number of them remain in the germinal epithelium near the mesentery. The larger cells are 13 microns in diameter, and their cytoplasm is increasing. The nuclei of these cells are 8 microns in diameter. The average cross-section contains about six primordial germ-cells in the germinal epithelium.

Several differences may be observed between the right and left female gonad. The germinal epithelium of the left gonad is approximately twice as thick as that of the right. There are four to five times as many primordial germ-cells in the germinal epithelium of the left gonad as in that of the right. A greater number of primordial germ-cells is found in the medullary region of the left gonad than in the right.

Ovarium: After 191 hours there is an increase in the number of primordial germ cells scattered throughout the depth of the germinal epithelium. A rather definite layer of connective tissue separates the medullary and germinal epithelial regions. This connective tissue layer is the primordial albuginea. Prior to this time no germ-cells have been found in a state of mitosis, but division occurs in some cells at this period. The largest germ-cells are

11 microns in diameter, and the nuclei are between 5 and 6 microns. The number of germ-cells in the germinal epithelium has doubled as compared with the 177-hour embryo. There is little increase in the number of germ-cells in the right gonad. The venous blood supply is greatly increased in the medullary portion of the female gonad.

After 206 hours the primordial germ-cells in the left female gonad are showing frequent division. Much of the activity occurs in the deeper parts of the germinal epithelium where small groups of two, three, or four cells occur in some phase of mitosis.

At 213 hours the primordial germ-cells are numerous in the left ovary. (Fig. 44). They are found in groups of three to six. Mitotic activity has increased, and with this cellular increase, the primordial albuginea is pushed into the medulla. The proliferation of primordial germ-cells into groups gives the germinal epithelium next to the albuginea a lobulated appearance. These lobulated groups of germ-cells are termed cortical cords or cords of second proliferation. The cells resulting from the division of the primordial germ-cells are the oogonia.

Three types of cells make up the cortex of the ovary: The epithelial cells, the primordial germ-cells, and the oogonial cells. Large numbers of epithelial cells are present in the cortex. They possess long, thin nuclei (8 x 3 microns) which stain deeply. The cell borders are difficult to distinguish. The primordial germ-cells, of which there are few in the germinal epithelium, are approximately 10 microns in diameter, and

have a nucleus from 7 to 8 microns in diameter. The oogonial cells are smaller than the primordial germ-cells. They are from 7 to 8 microns in diameter, and their nuclei are round to oval, and contain coarse chromatin granules.

The germinal cells located in the medullary cords are similar to those found in the cortex. Those germ-cells in the medullary cords are widely scattered and have not been observed in mitosis.

The medullary cords are loosely arranged, and the spaces between the cords are filled with erythrocytes. Some of the medullary cords have developed lumina which are lined by medullary cells. These lumina occur in that portion of the medulla near the attachment of the left ovary to the mesonephros. The medullary cords are increasing rapidly in length.

The right ovary is now composed mainly of medullary cords similar to those of the left gonad. The germinal epithelium consists of epithelial cells from the peritoneum. The albuginea is located just beneath the peritoneal epithelium. A few primordial germ-cells are present in the medullary cords.

At 228 hours the increased number of oogonia has produced a more distinct lobulation of the germinal epithelium. These lobulations are separating from the germinal epithelium. The germinal epithelium stains more deeply than do the lobules of oogonial cells. The germinal epithelial layer is composed of elongated cells with elongated nuclei. The long axis of the germinal epithelial cell is perpendicular to the surface of the ovary. Occasionally an oogonial cell is present between the germinal epithelial

cells at the surface of the ovary. This arrangement divides the cortical portion of the ovary into two distinct zones. The deeper layers of cells attached to the germinal epithelial cell layer are the germinative buds which later become the cortical cords.

The cortical region is distinctly separated from the medulla by the tunica albuginea. As the germinative buds push into the medulla, the area between two buds becomes filled with stroma or connective tissue.

The medulla of the right ovary is little changed from that of the 213-hour embryo. However, the lumina in the deeper portions of the medullary cords are more numerous, and those already present have become larger.

In the right ovary at 228 hours the germinal epithelium is reduced to a single layer of cuboidal cells which stain deeply. Just beneath the germinal epithelium there is a thin layer of connective tissue which is comparable to the albuginea of the left ovary. The main portion of the right female gonad is composed of medullary cords. There are also lumina in some of these cords, but they are smaller and less numerous than those of the left ovary. There is more stroma between the medullary cords of the right than of the left ovary. A few primordial germ-cells are present in the medullary cords. They have no regular distribution but may be found from the surface to the deepest portion of the cord.

There is no distinct cortex. A few cells just beneath the germinal epithelium resemble oogonia.

At 240 hours the cortical cords of oogonia are more numerous and some are separated from the germinal epithelium by connective tissue. (Fig. 47).

Much connective tissue separates the germinative cortical buds from each other. Few of the oogonial cells are in a state of mitosis. There is an increase in the number of primordial germ-cells in the germinal epithelium.

The medullary region has more cords presenting lumina. Many of the cells lining the lumina are in a state of mitosis.

The germinal epithelium covering the right ovary at 240 hours consists of a flat mesothelial cell layer. (Fig. 46). Just beneath the layer of germinal epithelium the stroma is well developed. The right ovary consists primarily of medullary cords, of which many contain lumina, and primordial germ-cells. The primordial germ-cells are slightly larger than those found in the left ovarian medulla. They measure 10 to 12 microns in diameter, while the nuclei measure 6 to 8 microns in diameter.

At 272 hours the cortical cell buds have increased in length enough to be called cortical cords, since they measure from 80 to 90 microns in length. The tunica albuginea is very distinct.

At 284 hours as many as 10 oogonia may be counted in a single section of one cortical cord. In some areas the cortical cords extend deeply into the medulla, but the two zones are separated by the tunica albuginea. The germinal epithelium consists of a single layer of cuboidal to columnar cells.

Most of the medulla is converted into tubules with wide lumina. Some of these lumina are present just beneath the tunica albuginea. Occasionally a distended medullary cord contains groups of granular primordial germ-cells.

The right ovary at 284 hours appears as a mass of distended medullary cords. (Fig. 49). The lumina of the cords are wide and bounded by a low, deeply staining epithelium. A few primordial germ-cells are found in and between the medullary cords.

At 307 hours the most pronounced activity in cordical cell cord production occurs at the anterior and posterior extremities of the left ovary. The cortical cords are longest at these two points. At 319 hours if a cortical cord is properly cut as many as 20 oogonia may be counted in a single section of one cord. There is also an increase in the number of distended medullary tubules. (Table 3). At 331 hours the cortical cords are not only extending in length but are expanding in width. (Fig. 50). The expansion in cortical cord width causes the stroma between them to become compact. Many of the cords measure .1 mm. in length.

The right ovary at 331 hours is rapidly becoming rudimentary as compared with the left ovary. (Table 3). The number of distended tubules has markedly increased causing the remaining medullary cords and stroma to arrange in strands.

At 345 hours many of the cortical cords have separated from the single layer of germinal epithelium. A layer of connective tissue, the true tunica albuginea, now lies between the germinal epithelium and the cortical cords. The primordial albuginea still separates the cortical cords and the medulla. At 357 hours the cortical cords have increased in length to from 1.7 to 2 mm.

In the 388 hour embryo the cortex and medulla of the left ovary stain distinctly. (Fig. 51). The germinal epithelium consists of a single layer of columnar epithelial cells. The tunica albuginea just beneath the germinal epithelium has become well developed. The cortical cords have increased in length to from 1.8 to 2.0 mm. The medullary tunica albuginea is distinct. The distended tubules of the medulla are most numerous near the ovarian attachment to the mesonephros. Germ-cells still persist between and in the medullary tubules. This histological picture exists until hatching. (Fig. 54).

Testis: After 177 hours the germinal epithelium of the male chick, in most instances, has been reduced to a single layer of cuboid cells. In certain areas the germinal epithelium appears as a two-cell layer. At these points the sexual cords are still attached to the germinal epithelium. However, for the most part all connections with the germinal epithelium and the seminiferous cords are lost as a result of condensation of mesenchyme, just under the germinal epithelium, to form the tunica albuginea.

The male gonads have a very narrow attachment with the mesonephros. This factor seems to orient the seminiferous cords so that they are arranged obliquely toward the attachment of the gonad. The cords are undulating, and are separated from each other by a thin layer of stroma.

The seminiferous cords, which are generally two cells in thickness, are made up of two kinds of cells, peritoneal cells from the germinal epithelium, and primordial germ-cells. The peritoneal cells are many times



Table 3.

Average Length X Width Measurements of the Ovaries  
of Chick Embryos With Increasing Age

| Number of<br>embryos | Age in<br>hours | Left<br>ovary<br>(mm.) | Right<br>ovary<br>(mm.) |
|----------------------|-----------------|------------------------|-------------------------|
| 5                    | 165             | 3.00 x 1.00            | 1.50 x .90              |
| 4                    | 191             | 3.75 x 1.10            | 2.00 x .80              |
| 10                   | 240             | 4.20 x 1.10            | 2.20 x .60              |
| 4                    | 260             | 4.20 x 1.20            | 2.00 x .40              |
| 5                    | 284             | 4.50 x 1.30            | 2.00 x .30              |
| 5                    | 307             | 5.20 x 1.30            | 2.30 x .80              |
| 5                    | 331             | 5.70 x 1.70            | 2.00 x .50              |
| 5                    | 357             | 6.00 x 2.00            | 3.50 x .70              |
| 5                    | 388             | 6.20 x 2.10            | 2.50 x .50              |
| 5                    | 412             | 7.50 x 2.10            | 2.80 x .60              |
| 5                    | 438             | 7.70 x 2.10            | 3.50 x 1.00             |
| 5                    | 462             | 7.80 x 2.50            | 3.00 x .80              |
| 5                    | 474             | 7.85 x 3.00            | 2.00 x .50              |
| 10                   | 498             | 8.10 x 3.20            | 3.50 x .70              |

more numerous than the primordial germ-cells. On longitudinal section of the male gonads, it seems that more primordial germ cells are found at the anterior and posterior poles than in the central region. These cells are small, measuring about 10 microns in diameter. The nuclei are 6 microns in diameter, and possess clear cytoplasm. For growth changes in the male see Table 4.

Histologically, at 191 hours the male testes are little changed except that the tunica albuginea has become more distinct. No mitotic activity is observed among the germ-cells. The stroma remains unchanged. (Table 4).

After 206 hours mitosis is infrequent in the primordial germ-cells. Some mitoses are located near the attachment of the gonad, and also near a rich blood supply. The seminiferous cords are more loosely arranged and the stroma has increased slightly.

After 213 hours a marked change has occurred in the testes. (Fig. 45). They show a greatly increased amount of stroma between the seminiferous cords, and the tunica albuginea is thickened. Any increase in size of the testes is largely the result of the increased amounts of connective tissue. The stroma cells have round to oval nuclei measuring 3 to 4 microns in diameter. The cytoplasm is drawn out into processes which anastomose with neighboring cells.

The seminiferous cords now form an irregular network and are convoluted. Some cords are only visible in a field for a short distance. The cords are more compact at the anterior and posterior poles than in the central region of the testes.

A definite basement membrane surrounds the seminiferous cords. This membrane was acquired when the cords proliferated from the germinal epithelium. The seminiferous cords are two cells in thickness and are composed principally of the peritoneal type cell. Rather frequently a primordial germ-cell is found in the seminiferous cords. These two kinds of cells appear as a syncytium, but are easily differentiated on the basis of their nuclei. The primordial germ-cell nuclei are from 6 to 8 microns, while the peritoneal cell nuclei are from 3 to 4 microns in diameter. The germ-cell nuclei are clear and possess one or two nucleoli. The seminiferous cords vary in diameter from 11 to 16 microns depending upon how they are sectioned. The cords are thicker at those points where germ-cells are located. Many capillaries are visible in the stroma.

The testes of the 228-hour embryo resemble those of the 213-hour embryo in structure. Increased amounts of stroma cause the testes to become more rounded. The testes are still attached to the mesonephros by a narrow portion of tissue.

The germinal epithelium stains deeply and the cells are of the low cuboidal type. Occasionally a primordial sex cell is found in the germinal epithelium. The layer of stroma just beneath the germinal epithelium is thicker.

Three kinds of cells now compose the seminiferous cords. The predominating cell is the peritoneal cell. A few spermatogonia are present in the seminiferous cords, and they are similar to the oogenia in the 228-hour ovary. The primordial germ-cells are from 8 to 10 microns in diameter;

their nuclei are from 5 to 7 microns in diameter. The spermatogonia measure from 6 to 8 microns in diameter; their nuclei are from 4 to 5 microns. The primordial germ-cells and the spermatogonia have no definite position in the seminiferous cords.

The seminiferous cords as a group form a network. They stain deeply and stand out sharply against the lighter connective tissue background. Mitotic figures are present in the nuclei of the peritoneal cells, the primordial germ-cells, and the connective tissue stromal cells.

At 240 hours many primordial germ-cells are present in the seminiferous cords. A few spermatogonia appear, but are widely scattered. The stroma of the testes is more loosely arranged than previously. There has also been a slight increase in the amount of stromal tissue, and therefore, an increase in size of the testes which are almost separated from the mesonephros.

The seminiferous cords at 252 hours have an average diameter of from 20 to 22 microns. Many primordial germ-cells are actively dividing, and spermatogonia are present in the seminiferous cords. The peritoneal cells are not active. There is no definite arrangement of cells in the seminiferous cords. Increase in the diameter of the cords has caused the stroma to become more compact.

At 260 hours no change except growth has taken place in the testes.

At 272 hours the seminiferous cords have an average diameter of 25 microns. (Fig. 48). All of the sexual elements are seeking a placement

against the basement membrane of the cord. The nuclei of the peritoneal cells are also located basally toward the basement membrane. Occasionally a seminiferous cord contains a small lumen. The lumina as yet are not continuous. A few interstitial cells are found within the connective tissue stroma between the seminiferous cords. Many mitotic figures are present among the germ-cells.

After 295 hours of development the testes are cylindrical and have approximately the same diameter on the left and right sides of the body. (Table 4). They are still attached to the mesonephros by a very narrow strip of tissue. The sexual cords are increasing in length and are becoming folded, producing a network-like appearance.

The testes at 307 hours are typically elongated and cylindrical. The sexual cells continue to divide in the seminiferous cords. Some cords have lumina which are not continuous. A few interstitial cells are present in the testicular stroma.

At 319 hours there is a continued increase in stroma. The area occupied by the stroma now exceeds that of the sexual cords.

At 331 hours of development the testes continue to increase in diameter as a result of growth of the seminiferous cords and stroma. (Fig. 52). The seminiferous tubules vary in diameter from 30 to 35 microns. A slight increase in the number of interstitial cells has occurred, and they are scattered in groups of from one to six cells.

After 345 hours the testes remain as previously described except for an increase in interstitial cells.

In the 375-hour chick embryos the testes present no noticeable histological changes except growth. (Table 4).

The testes at 388 hours remain as previously described except for growth. They seem to be increasing in length more rapidly than in diameter. (Table 4).

At 400 hours the diameter and length of the seminiferous cords have increased. There are many cords which have a diameter between 35 and 40 microns. As a result of growth of the seminiferous cords there is a crowding of the stroma into strands. Most of the primordial germ-cells have divided, giving rise to spermatogonia. Thus far no evidence has been found regarding maintenance of the peritoneal cells, since no cells have been found in a phase of mitosis, yet they do not decrease in number. Many of the spermatogonia have assumed a position next to the basement membrane of the seminiferous cord. In many of the cords lumina are present but are not continuous. There is a very slight increase in the number of interstitial cells.

The testes at 412 hours show evidence of further increase in size. (Table 4). Most of the primordial germ-cells have changed into spermatogonia by division. Many of the spermatogonia have a peripheral position next to the basement membrane of the cord. A few scattered lumina are present, but are not continuous in the seminiferous cords. The interstitial cells have not increased in number. The stroma is becoming very compact.

The testes at 438 hours are elongated and cylindrical in shape, and are enveloped by a thin connective tissue layer, the tunica albuginea. The seminiferous cords are composed of two kinds of cells, the peritoneal or supporting cells form the largest portion of the seminiferous cords. Their nuclei are located side by side near the periphery of the cord, next to the basement membrane. Many of the spermatogonia are located near the basement membrane. The cords seem to be growing in length and are more branched than previously. There are more interstitial cells present.

At 450 hours the testes continue to increase in size. (Table 4).

After 462 hours the seminiferous cords are massive with lumina appearing in many and extending for some distance. The seminiferous cords are growing at the expense of the stroma which is considerably reduced in quantity. The interstitial cells are not increasing.

In the 498-hour embryo the seminiferous cords have become massive, their diameters varying between 30 and 40 microns. (Fig. 54). The stroma in some cases has been reduced in quantity. The interstitial tissue appears in amounts similar to that for the 438-hour embryo. The cells within the seminiferous cords have a definite arrangement. The nuclei of both the spermatogonia and supporting cells are placed against the basement membrane so that their long axes are at right angles to the long axis of the seminiferous cords. Therefore, the largest amount of cytoplasm in these two kinds of cells is toward the lumen of the cord. Some of the cords have lumina, but these are not continuous throughout the length of the cord.

Table 4.

Average Length X Width Measurement of the Testes of  
Chick Embryos With Increasing Age

| Number of<br>embryos | Age in<br>hours | Left<br>testis<br>(mm.) | Right<br>testis<br>(mm.) |
|----------------------|-----------------|-------------------------|--------------------------|
| 5                    | 191             | 2.80 x .90              | 2.40 x .60               |
| 5                    | 213             | 3.00 x .90              | 2.50 x .70               |
| 10                   | 240             | 3.00 x 1.00             | 3.00 x .80               |
| 6                    | 260             | 3.40 x 1.10             | 3.10 x .80               |
| 5                    | 284             | 3.50 x 1.20             | 3.20 x .90               |
| 5                    | 307             | 4.00 x 1.20             | 3.50 x 1.10              |
| 5                    | 331             | 4.25 x 1.20             | 3.70 x 1.10              |
| 5                    | 357             | 5.10 x 1.30             | 4.00 x 1.20              |
| 5                    | 388             | 6.00 x 1.40             | 5.00 x 1.20              |
| 5                    | 412             | 6.20 x 1.40             | 5.50 x 1.20              |
| 5                    | 438             | 6.20 x 1.50             | 5.70 x 1.25              |
| 5                    | 462             | 6.25 x 1.70             | 6.00 x 1.30              |
| 5                    | 474             | 6.30 x 1.75             | 6.00 x 1.25              |
| 10                   | 498             | 6.35 x 1.80             | 6.10 x 1.50              |



The cords form a definite network and extend obliquely toward the remnants of the mesonephros.

Growth of the Endocrine Organs: Recent investigations of the relation of the endocrine organs to growth have induced a study of this in the chick embryo. No complete data on the endocrine organ weights of the Single-comb White Leghorn chick embryos were available in the literature.

The data presented in this investigation are concerned with possible sex differences in the weights of the hypophysis, the thymus, thyroids, adrenals, ovaries and testes of Single-comb White Leghorn chick embryos from ten to twenty-one days of incubation.

The data on the body weights of both the male and female embryos are summarized in Table 5. The figures show that growth is most rapid in both sexes between eleven and twelve days of incubation, and that the female embryos are rather consistently heavier than the males. There is slightly more variability in the weights of the male embryos than in the weights of the female embryos.

It is interesting to note in Table 6 that there is a progressive increase in the mean weights of the hypophyses of both sexes prior to sixteen days of incubation, after which time there is a plateauing of these figures. However, when the means are corrected for body weight, there is a slow but progressive decrease in these percentage figures from ten to twenty-one days of the incubation period. (Fig. 56). If there is a difference between the weights of the embryonic hypophyses of the male and female

Table 5.

Means and Standard Deviations of the Wet  
Body Weight of Chick Embryos

| Number of embryos |    | Days incubated | Mean (gms.) |       | Standard Deviation (gms.) |      |
|-------------------|----|----------------|-------------|-------|---------------------------|------|
| ♂                 | ♀  |                | ♂           | ♀     | ♂                         | ♀    |
| 10                | 10 | 10             | 2.26        | 2.01  | .16                       | .23  |
| 10                | 10 | 11             | 2.61        | 2.75  | .39                       | .35  |
| 10                | 10 | 12             | 4.34        | 4.52  | .69                       | .64  |
| 10                | 10 | 13             | 6.29        | 6.42  | .72                       | .89  |
| 10                | 10 | 14             | 8.76        | 9.35  | 1.18                      | .72  |
| 10                | 10 | 15             | 12.67       | 12.80 | 1.78                      | 1.85 |
| 10                | 10 | 16             | 15.85       | 16.25 | 1.83                      | 1.52 |
| 10                | 10 | 17             | 18.60       | 20.00 | 1.57                      | 1.24 |
| 10                | 10 | 18             | 20.36       | 23.40 | 3.15                      | 1.66 |
| 10                | 10 | 19             | 23.75       | 23.60 | 2.41                      | 2.88 |
| 10                | 10 | 20             | 31.29       | 31.58 | 2.16                      | 2.32 |
| 10                | 10 | 21             | 33.70       | 33.75 | 4.26                      | 3.78 |

Table 6.

Means, Standard Deviations and Percentage Weight  
of the Hypophyses of Chick Embryos

| Number of embryos |    | Days incubated | Mean (mgms.) |      | σ (mgms.) |     | Hypophysis (mgms.)<br>Wet body weight (gms.) X 100 |      |
|-------------------|----|----------------|--------------|------|-----------|-----|--|------|
| ♂                 | ♀  |                | ♂            | ♀    | ♂         | ♀   | ♂  | ♀    |
| 10                | 10 | 10             | .31          | .29  | .07       | .05 | .014   | .014 |
| 10                | 10 | 11             | .37          | .37  | .03       | .02 | .014   | .013 |
| 10                | 10 | 12             | .50          | .50  | .10       | .15 | .012   | .011 |
| 10                | 10 | 13             | .90          | .83  | .09       | .12 | .014   | .013 |
| 10                | 10 | 14             | .90          | .89  | .16       | .29 | .010   | .010 |
| 10                | 10 | 15             | 1.06         | .94  | .37       | .31 | .008   | .007 |
| 10                | 10 | 16             | 1.42         | 1.42 | .15       | .22 | .009   | .009 |
| 10                | 10 | 17             | 1.47         | 1.43 | .29       | .20 | .008   | .007 |
| 10                | 10 | 18             | 1.45         | 1.44 | .18       | .15 | .007   | .006 |
| 10                | 10 | 19             | 1.42         | 1.42 | .12       | .12 | .006   | .006 |
| 10                | 10 | 20             | 1.41         | 1.42 | .11       | .14 | .005   | .004 |
| 10                | 10 | 21             | 1.48         | 1.42 | .09       | .08 | .004   | .004 |

$$\text{RATIO} : \frac{\text{HYPOPHYSIS WEIGHT (MGMS)}}{\text{WET BODY WEIGHT (GMS)}} \times 100$$

$$\text{RATIO} : \frac{\text{THYMUS WEIGHT (MGMS)}}{\text{WET BODY WEIGHT (GMS)}} \times 100$$

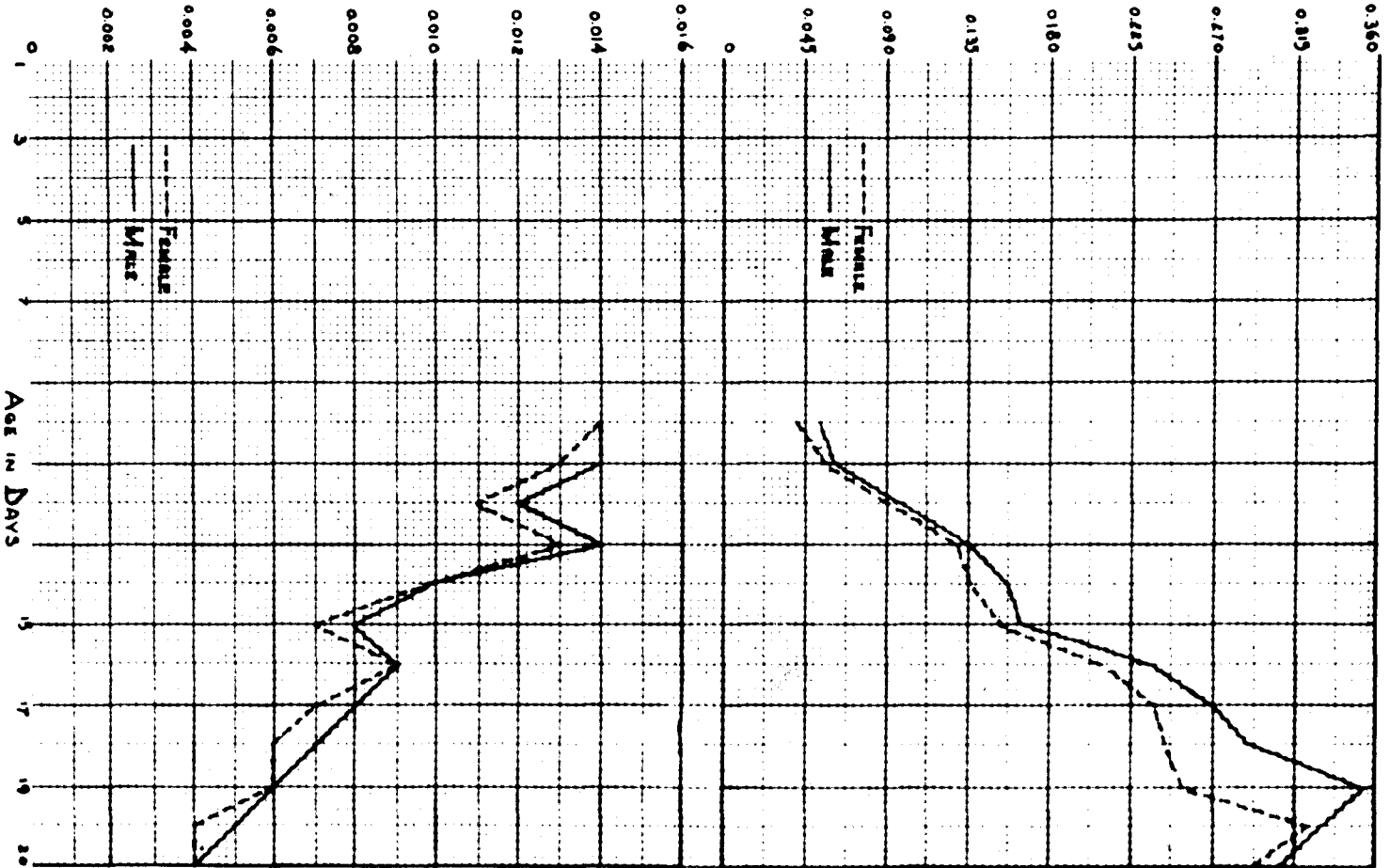


FIG. 55 THE CHANGE IN RELATIVE THYMUS WEIGHT OF CHICK EMBRYOS WITH INCREASED AGE.  
 FIG. 56 THE CHANGE IN RELATIVE HYPOPHYSIS WEIGHT OF CHICK EMBRYOS WITH INCREASED AGE.

embryos, it is slightly in favor of a heavier male hypophysis. This statement is based on the fact that at no time during the incubation period are the hypophyses of the female embryos heavier than those of the male when corrected for body weight. (Fig. 56).

Latimer (76) has presented data on the postnatal growth of the Single-comb White Leghorn fowl hypophyses in which he found no appreciable sex difference when the weights are plotted against body weight. If there is a difference, it is in favor of a heavier male hypophysis.

If the weight of a gland is indicative of its functional activity, it might be concluded that the hypophysis is most active at the close of the incubation period, and least active at ten and eleven days. Some evidence to defend the statement that the weight and the activity of a gland are associated, is presented by Juhn and Mitchell (67). These workers found that castration induced a hypertrophy of the hypophysis with a significant increase in the percentage weight of the gland as compared with that of normal males. This increase in weight is produced by the storage of the gonadotropic hormone in the pars glandularis.

The thymus of the chick embryos follows the usual course of development in that there is a progressive increase in the mean weights of both sexes from ten to twenty-one days of the incubation period. The mean weights are consistently less for the female as compared with the male embryos. This is also true of the percentage gland weights. (Table 7).

It is interesting to note that there is a rather abrupt and marked decrease in the thymic weights of both sexes just at hatching time. (Fig. 55).

Table 7.

Means, Standard Deviations and Percentage Weight  
of the Thymi of Chick Embryos

| Number of embryos |    | Days incubated | Mean (mgms.) |        | S.D. (mgms.) |       | Thymus (mgms.)<br>Wet body weight (gms.) X 100 |      |
|-------------------|----|----------------|--------------|--------|--------------|-------|--|------|
| ♂                 | ♀  |                | ♂            | ♀      | ♂            | ♀     | ♂  | ♀    |
| 10                | 10 | 10             | 1.18         | .84    | .34          | .34   | .052   | .042 |
| 10                | 10 | 11             | 1.60         | 1.60   | .66          | .51   | .061   | .058 |
| 10                | 10 | 12             | 4.26         | 4.11   | 1.40         | 2.34  | .098   | .091 |
| 10                | 10 | 13             | 8.36         | 8.33   | 2.41         | 2.47  | .133   | .130 |
| 10                | 10 | 14             | 13.90        | 12.80  | 3.20         | 1.43  | .158   | .137 |
| 10                | 10 | 15             | 20.70        | 20.30  | 3.44         | 4.19  | .163   | .159 |
| 10                | 10 | 16             | 37.90        | 34.22  | 12.81        | 7.86  | .239   | .211 |
| 10                | 10 | 17             | 50.00        | 47.20  | 13.67        | 7.70  | .269   | .236 |
| 10                | 10 | 18             | 59.17        | 57.90  | 17.45        | 12.56 | .291   | .247 |
| 10                | 10 | 19             | 83.90        | 60.00  | 15.15        | 22.17 | .353   | .254 |
| 10                | 10 | 20             | 104.00       | 101.36 | 14.07        | 19.76 | .332   | .321 |
| 10                | 10 | 21             | 104.38       | 98.28  | 19.58        | 23.45 | .310   | .291 |

This percentage decrease is not a permanent one in view of the data of Latimer (76). He stated that this percentage rises from a little less than 0.3 per cent of the net body weight to 0.46 per cent at one hundred and ten days. After this time there is a decrease to approximately 0.05 per cent for adult chickens.

The coefficient of variability is rather great for the thymus of both sexes. Some of this variability is the result of difficulty in getting the thymic lobes dissected free of fascia and fat. However, it is a fact that the thymic tissue weights vary considerably between individuals even though they have the same body weight, age, and sex.

The thyroid glands of both sexes develop slowly but progressively. (Table 8). These percentage figures show that the thyroid glands of both sexes are largest after nineteen days of incubation. If the weight of the gland is indicative of its activity, it might be concluded that the thyroid glands of both sexes are least active from sixteen to twenty-one days of incubation. (Fig. 57).

Leonard and Richter (78) found no significant sex difference in the weights of the thyroids in the bantam. Juhn and Mitchell (67) observed that the thyroids of the Brown Leghorn are heavier in the male than in the female birds. Latimer (76) obtained little evidence indicative of a sex difference in the weights of the growing Single-comb White Leghorn. Brennan (16) observed that during the first thirty postnatal days the thyroid glands of both sexes decrease in relative size with age, but that this is much more marked in the pullets.

$$\text{RATIO} = \frac{\text{THYROID WEIGHT (MGMS)}}{\text{WET BODY WEIGHT (GMS)}} \times 100$$

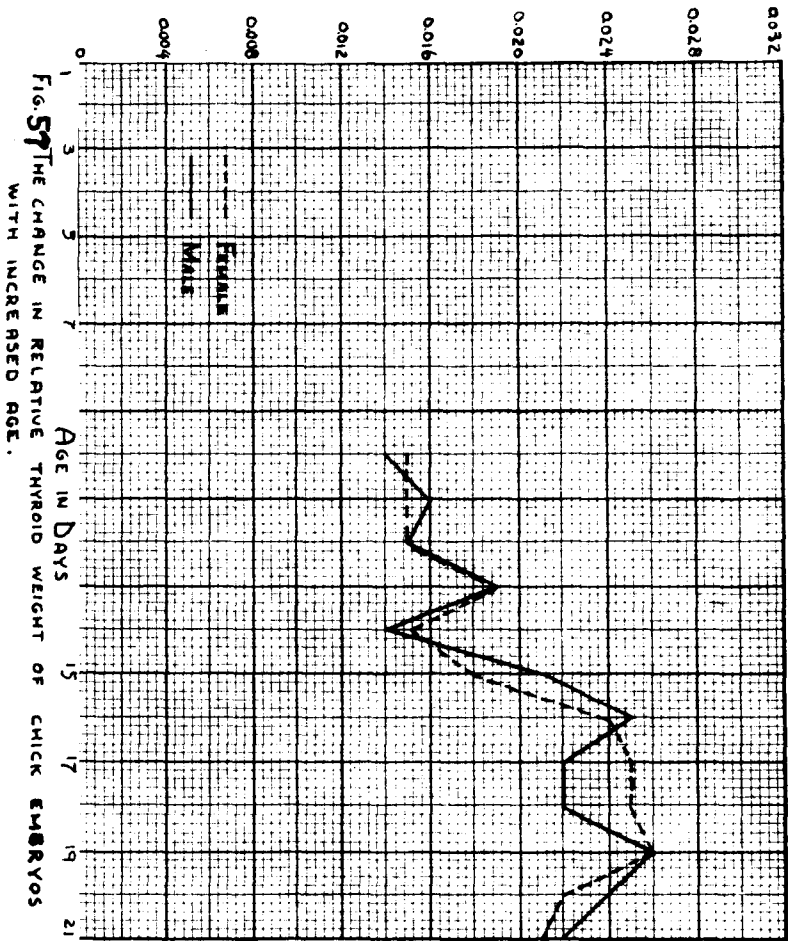


FIG. 57 THE CHANGE IN RELATIVE THYROID WEIGHT OF CHICK EMBRYOS WITH INCREASED AGE.

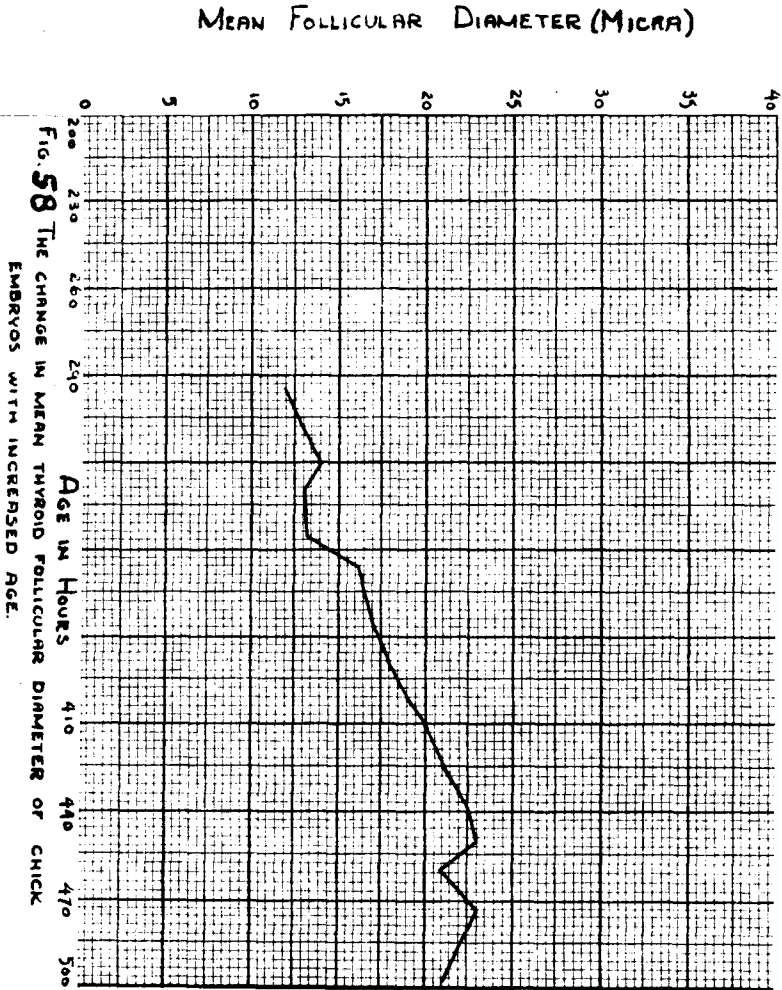


FIG. 58 THE CHANGE IN MEAN THYROID FOLLICULAR DIAMETER OF CHICK EMBRYOS WITH INCREASED AGE.



Table 8.

Means, Standard Deviations and Percentage Weight  
of the Thyroid Glands of Chick Embryos

| Number of embryos |    | Days incubated | Mean (mgms.) |      | σ (mgms.) |      | Thyroids (mgms.)<br>Net body weight (gms.) X 100 |      |
|-------------------|----|----------------|--------------|------|-----------|------|--|------|
| ♂                 | ♀  |                | ♂            | ♀    | ♂         | ♀    | ♂  | ♀    |
| 10                | 10 | 10             | .32          | .31  | .07       | .06  | .014   | .015 |
| 10                | 10 | 11             | .43          | .41  | .09       | .09  | .016   | .015 |
| 10                | 10 | 12             | .66          | .67  | .19       | .13  | .015   | .015 |
| 10                | 10 | 13             | 1.22         | 1.22 | .38       | .37  | .019   | .019 |
| 10                | 10 | 14             | 1.22         | 1.40 | .20       | 1.01 | .014   | .015 |
| 10                | 10 | 15             | 2.77         | 2.35 | .98       | .51  | .021   | .018 |
| 10                | 10 | 16             | 4.02         | 3.91 | .71       | 1.18 | .025   | .024 |
| 10                | 10 | 17             | 4.00         | 4.98 | .73       | 1.22 | .022   | .025 |
| 10                | 10 | 18             | 4.45         | 5.82 | .71       | .91  | .022   | .025 |
| 10                | 10 | 19             | 6.17         | 6.15 | .97       | .89  | .026   | .026 |
| 10                | 10 | 20             | 7.57         | 6.82 | 1.00      | 1.12 | .024   | .022 |
| 10                | 10 | 21             | 7.40         | 6.93 | 1.19      | 1.28 | .022   | .021 |

Sun (142) presented a graph showing the weight per pair of thyroid glands from nine to twenty and one-fourth days. Sun determined the total iodine content per pair of thyroid glands from the tenth to the twenty and one-fourth day of incubation.

There is a progressive increase in the mean weights of the adrenal glands for both sexes from the tenth to the twenty-first day of incubation. There is a rather gradual decrease in the percentage weights of the adrenals in both sexes from the eleventh to the twenty-first day of incubation. (Fig. 59). It is also noted from Table 9 that there is marked variability among the adrenal gland weights.

Juhn and Mitchell (67) observed that in adult Brown Leghorn chickens no pronounced sex differences are present in the weights of the adrenals. Latimer, (76) working with Single-comb White Leghorn chickens, observed that the adrenal glands are somewhat variable in weight but show no sex differences. Breneman (16) found in White Leghorn chicks from the fifth to the thirtieth day after hatching that the adrenal glands are of a uniform proportion throughout the series, becoming lighter in relative size at the thirtieth day. Leonard and Richter (78) found no sex difference in size of the adrenals of the bantam fowl.

Sun (142) presented data for the weight per pair of adrenal glands from the nine and one-half through the twentieth day of incubation. Sun also determined the epinephrine content per gram of gland tissue, and total epinephrine content per pair of adrenal glands. The epinephrine content of the glands increased in absolute and relative amounts. If

$$\text{RATIO} : \frac{\text{GLAND WEIGHT (MGMS)}}{\text{WET BODY WEIGHT (GMS)}} \times 100$$

$$\text{RATIO} : \frac{\text{ADRENAL WEIGHT (MGMS)}}{\text{WET BODY WEIGHT (GMS)}} \times 100$$

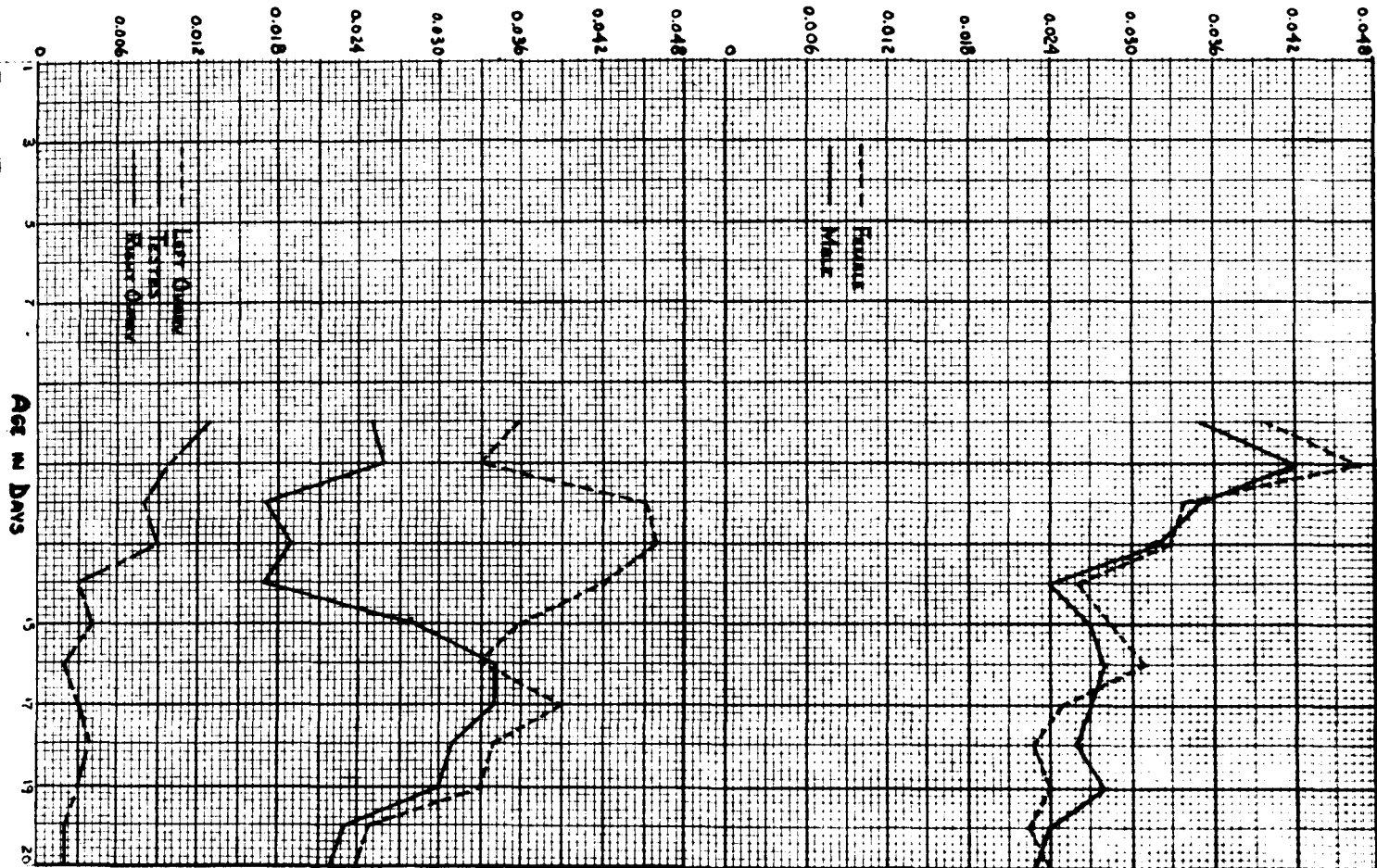


FIG. 59 THE CHANGE IN RELATIVE ADRENAL WEIGHT OF CHICK EMBRYOS WITH INCREASED AGE.  
 FIG. 60 THE CHANGE IN RELATIVE OVARY AND TESTIS WEIGHT OF CHICK EMBRYOS WITH INCREASED AGE.

Table 9.

Means, Standard Deviations and Percentage Weight  
of the Adrenal Glands of Chick Embryos

| Number of embryos |    | Days incubated | Mean (mgms.) |      | σ (mgms.) |      | Adrenals (mgms.)<br>Wet body weight (gms.) X 100 |      |
|-------------------|----|----------------|--------------|------|-----------|------|--|------|
| ♂                 | ♀  |                | ♂            | ♀    | ♂         | ♀    | ♂  | ♀    |
| 10                | 10 | 10             | .80          | .80  | .28       | .21  | .035   | .040 |
| 10                | 10 | 11             | 1.10         | 1.30 | .49       | .59  | .042   | .047 |
| 10                | 10 | 12             | 1.52         | 1.54 | .48       | .36  | .035   | .034 |
| 10                | 10 | 13             | 2.03         | 2.10 | .53       | .67  | .032   | .033 |
| 10                | 10 | 14             | 2.14         | 2.44 | .35       | .49  | .024   | .026 |
| 10                | 10 | 15             | 3.47         | 3.64 | .93       | .62  | .027   | .028 |
| 10                | 10 | 16             | 4.36         | 5.05 | .53       | .96  | .028   | .031 |
| 10                | 10 | 17             | 4.98         | 5.02 | .83       | .71  | .027   | .025 |
| 10                | 10 | 18             | 5.23         | 5.48 | .94       | .73  | .026   | .023 |
| 10                | 10 | 19             | 6.64         | 5.68 | 1.13      | 1.16 | .028   | .024 |
| 10                | 10 | 20             | 7.44         | 6.95 | 1.03      | .95  | .024   | .022 |
| 10                | 10 | 21             | 7.85         | 8.06 | 1.11      | 1.32 | .023   | .024 |

this curve is compared with the curve of percentage gland weight determined from this study it is noted that the curves proceed in opposite directions. (Fig. 59).

The mean weights of the left ovaries increase until the eighteenth day of incubation when they begin to plateau. (Fig. 60). When the left ovary is considered in percentage of the body weight, the largest figures occur between the twelfth and fourteenth day, and the smallest between the twentieth and twenty-first day of incubation. (Table 10). The figure for the seventeenth day is large, and is the result of sampling error, since the coefficient of variability was very high.

The mean weights of the right ovaries are extremely variable. The percentage weights decrease from the tenth to the twenty-first day. (Fig. 60). The right ovaries are so small that much difficulty is experienced in dissecting them out, and as a result, the coefficients of variability are extremely great. (Table 10).

Breneman (16) has data to show that the female gonad increases in weight from the fifth day after hatching until the twentieth day, when the figures begin to plateau. Latimer (76) observed that in Single-comb White Leghorn chickens the ovaries are extremely variable in weight.

The mean testes weights increase progressively from the tenth to twenty-first day of incubation. (Table 11). From the nineteenth to the twenty-first day of incubation the testes increases very little in mean weight. Considering the testes as percentages of the total body weight, they are

Table 10.

Means, Standard Deviations and Percentage Weight of  
the Right and Left Ovaries of Chick Embryos

| Number of<br>embryos incubated | Days | Mean (mgms.) |      | σ (mgms.) |      | Ovaries (mgms.)<br>Wet body weight (gms.) X 100 |      |
|--------------------------------|------|--------------|------|-----------|------|---|------|
|                                |      | Right        | Left | Right     | Left | Right   | Left |
| 10                             | 10   | .26          | .72  | .06       | .23  | .013  | .036 |
| 10                             | 11   | .28          | .92  | .10       | .22  | .010  | .033 |
| 10                             | 12   | .36          | 2.02 | .09       | .45  | .006  | .045 |
| 10                             | 13   | .55          | 2.93 | .26       | .79  | .009  | .046 |
| 10                             | 14   | .31          | 3.95 | .25       | .93  | .003  | .042 |
| 10                             | 15   | .57          | 4.60 | .31       | .97  | .004  | .036 |
| 10                             | 16   | .25          | 5.33 | .09       | 1.29 | .002  | .033 |
| 10                             | 17   | .69          | 7.80 | .32       | 2.56 | .003  | .039 |
| 10                             | 18   | .85          | 8.00 | .52       | .84  | .004  | .034 |
| 10                             | 19   | .75          | 7.85 | .29       | 1.06 | .003  | .033 |
| 10                             | 20   | .56          | 7.96 | .38       | 1.18 | .002  | .025 |
| 10                             | 21   | .85          | 8.20 | .18       | .97  | .002  | .024 |

Table 11.

Means, Standard Deviations, and Percentage Weight  
of the Testes of Chick Embryos

| Number of<br>embryos | Days<br>incubated | Mean (mgms.) |          | Testes (mgms.)<br>Wet body weight (gms.) | X 100 |
|----------------------|-------------------|--------------|----------|--|-------|
|                      |                   | $\bar{x}$    | $\sigma$ |  |       |
| 10                   | 10                | .58          | .15      | .025                                     |       |
| 10                   | 11                | .68          | .17      | .026                                     |       |
| 10                   | 12                | .73          | .17      | .017                                     |       |
| 10                   | 13                | 1.22         | .36      | .019                                     |       |
| 10                   | 14                | 1.53         | .33      | .017                                     |       |
| 10                   | 15                | 3.60         | 1.82     | .028                                     |       |
| 10                   | 16                | 5.36         | 1.08     | .034                                     |       |
| 10                   | 17                | 6.38         | 1.47     | .034                                     |       |
| 10                   | 18                | 6.33         | 1.21     | .031                                     |       |
| 10                   | 19                | 7.08         | 2.06     | .030                                     |       |
| 10                   | 20                | 7.33         | .72      | .023                                     |       |
| 10                   | 21                | 7.50         | 1.17     | .022                                     |       |

smallest between the twelfth and fourteenth day, and largest between the sixteenth and nineteenth day of incubation. (Fig. 60). From the seventeenth day until hatching there is a gradual decrease in the percentage weight of the testes. In general, the testes are variable between individuals of the same group thus giving large coefficients of variability.

Breneman (16) obtained data to show that a definite increase in size takes place in the testes from the fifth to the fifteenth day of postnatal life, at which time they reach their maximum size in relation to body weight. Latimer (76) observed that the testes are very variable in the adult Leghorn chicken.



## DISCUSSION

Hypophysis cerebri

The observations concerning Seessel's pouch recorded in the present study are in agreement with those of Economo (34), Tilney (150), Bruni (18), Atwell and Sittler (8), Pfeiffer (107), and Lillie (79). Pfeiffer (103) reports that in the duck Seessel's pouch fuses with the ectodermal evagination and contributes to the adult gland. This does not appear to be the case in the chick, since at 148 hours of incubation Seessel's pouch has disappeared except for a bud of epithelial cells at the base of the hypophysial stalk near the oral cavity.

At 110 hours of incubation a definite hypophysial stalk has formed. Atwell and Sittler (8) stated that this structure was formed at 120 hours. In some embryos at 134 hours of incubation the hypophysial stalk is no longer patent. At 177 hours all embryos possessed a solid hypophysial stalk. (Fig. 3). Rahn (111) stated that the lumen closes at about nine days. At 191 hours of incubation the hypophysial stalk has disappeared in most embryos except for occasional clumps of epithelial cells. Atwell (7) reported that the cavity is discontinuous at seven days, and becomes subdivided during the next four days. The observations in this study indicate that few remnants of the hypophysial stalk are present after 228 hours of incubation, although a remnant was observed in an eighteen day chick embryo. Atwell (7) has found remnants of the hypophysial stalk in

a fifteen day chick embryo and has observed that the site of the attachment of the stalk to the rostral division of the anterior lobe persists at least until sixteen days of incubation. Müller (96), Economo (34), and Bruni (18) stated that atrophy of the stalk begins between the tenth and twelfth days of incubation. Tilney (150) found that it has disappeared by the eleventh day, while Stein (139) stated that this has occurred by the ninth day of development. Rahm (111) and Bruni (18) have occasionally found remnants of the stalk in the adult chicken.

The lateral lobes from which the tuberal processes arise may be recognized in the chick embryo at 60 hours of incubation. This observation is in agreement with that of Atwell and Sittler (8). It is evident that at 72 hours of incubation, the lateral lobes communicate with Rathke's pocket and are not formed independently of it. (Fig. 2). Woerdeman (171) considered that the lateral lobes arose independently of Rathke's pocket, and according to Rossi (121) the lateral lobes were secondary structures. A pair of "Seitensprossen" were observed in the hypophysis of the dove and chick by Economo (34), but no statement was made concerning their first appearance in the chick. Bruni (18) observed the presence of two "lobi laterali" in the chick at 82 hours of incubation.

At 120 hours of incubation the lateral lobes have increased in size so that the transverse diameter of the gland, measured between the lateral extremities of the two lobes, is twice the transverse diameter of the proximal part of Rathke's pocket. The lateral lobes are now united by a

prominent median ridge at the cephalic extremity of the hypophysis. This ridge, according to Atwell and Sittler (8), doubtless corresponds to a vestigial "Vorraum" or corpus lobuli bifurcati" of other vertebrates as described by Woerdeman (171).

At six days, according to Atwell and Sittler (8), and at 148 hours of incubation, indicated by this study, the lateral lobes give rise to definite tuberal processes which extend dorsally toward the brain floor. (Fig. 3). These epithelial tuberal processes protrude from the middle of the ventral half of the pars glandularis.

The bilobed character of the pars glandularis is an interesting feature which has been known for some time. (Fig. 4). The origin of the bilobed condition can be traced back to the 134 hour embryo in which there appears a slight transverse constriction in the pars glandularis just posterior to the site of origin of the lateral lobes. (Fig. 3). The groove contains the internal carotid arteries. (Fig. 4). This condition was early illustrated by Rossi (121) but without descriptive comment. Economo (34) mentioned the "Knickungsstelle" or bending point of the hypophysis. (Fig. 3). Tilney (150) illustrated this condition, but presented no description. This groove was noted by Woerdeman (171) and described in the six day chick by Atwell and Sittler (8). If the terminology of Woerdeman (171) and Lups (85) is used, the posterior lobe of the pars glandularis might be thought of as being derived from Rathke's pocket proper; the anterior lobe as a composite of the Mittelraum, Vorraum and

Ventralsäckchen. Figure 9 of Lups article shows the Lobuli laterales or tuberal processes attaching to the Mittelraum. None of these investigators has followed the subsequent history of this constriction.

Atwell (7) followed the division of the pars glandularis into two parts, the rostral (or anterior) lobe and the caudal (or posterior) lobe. He made observations at the following stages: 7, 9, 11, 13, 15, 16, and 18 days of incubation, and one day after hatching. No attention is focused on the cytological changes.

Rahn (111) made morphological and cytological studies of a series of birds ranging from six days of incubation to the adult stage. Cellular differences were found in the two lobes. According to his work the caudal part (posterior lobe) represents typical pars glandularis tissue; the cephalic (anterior lobe) "is chiefly characterized by an exceedingly faint-staining acidophil of different color and finer granulation."

The order of differentiation of cell types is of interest. The first striking differentiation is seen at 191 hours of incubation. This observation is in agreement with Rahn (111). The nuclei and cytoplasm of the cells around the residual lumen exhibit a basophilia. The nuclei are large, rather irregular in outline, and contain two or three acidophilic staining nucleoli. This area around the lumen contains the oldest cells. The cells near the periphery of the gland are young and undifferentiated. Their nuclei are rather transparent and they contain little cytoplasm. It is rather difficult to classify the central differentiating cells, be-

cause they do not become the future basophils. The picture at 206 hours of incubation is somewhat advanced over the 191 hour embryos in that accumulations of basophilic colloid now exist in the cytoplasm on the proximal surface of the nuclei of those cells near the residual lumen. No change can be seen in the nucleoli. Rahn (111) indicated that this intracellular basophilic colloid is seen about the eighth day of development. Observations on the 213 and 228 hour embryos indicate that the basophilic differentiation has progressed further peripherally, but that most of the peripheral portion of the gland is still undifferentiated.

At 240 hours of development a second step in the differentiation of cell types occurs. Many of the basophilic cells in the anterior lobe now possess acidophilic granules in their cytoplasm. The nuclei of these cells are centrally located. This is in agreement with the observations of Rahn (111). Rahn also found that the acidophils appear first in the anterior tip of the cephalic (anterior) lobe. Although the differentiating acidophils are confined to the anterior lobe, this study does not show that they first appear in the anterior tip.

Two types of basophilic cells are present in the pars glandularis of the 240 hour embryo. The one type takes a very dark basophilic staining, and the other takes a very light basophilic staining. The few dark staining cells are scattered throughout both lobes, but in general are located at the periphery of the gland. These dark staining cells are regarded as the future basophils.

The observations presented indicate that the acidophils are developing from a transitional basophilic cell type. Rahn (111) used the term "transition, basophilic chromophobes" and "transitional chromophobes" for those cells which give rise to the acidophils. There seems to be no good reason for the use of the term "chromophobe" since these cells are not typically chromophobic in character.

At 319 hours of incubation typical acidophilic cells appear in the posterior lobe. Rahn (111) stated that this occurs on the eighteenth day.

From 331 to 375 hours of incubation a peculiar zonation of cells occurs. (Fig. 6). The postero-central area of the pars glandularis contains a preponderance of basophils, while the antero-peripheral area of the anterior lobe and the postero-peripheral area of the posterior lobe of the pars glandularis contains mostly acidophils. This particular zonation of cell types, however, does not persist after 388 hours of incubation.

After 388 hours of development pyknotic nuclei are common among the acidophils. Coupled with these stages of pyknosis is an increase in granulation within the cytoplasm. Severinghaus (131) stated that this condition would indicate the peak of granular accumulation. Rahn (111) has found that pyknotic nuclei are present among the acidophils from about the sixteenth day of incubation.

At 462 hours of development the two lobes of the pars glandularis become cellularly different. (Fig. 8). At the anterior tip of the anterior lobe the acidophils become slightly granular, and stain light pink to light

yellow. These cells show no tendency to become more strongly acidophilic. Proceeding posteriorly to the region of constriction, the number of these light staining cells decreases. Around the area of constriction there are a few deeply staining, granular acidophils, but preponderance of these cells is found in the posterior lobe. The weakly staining acidophils predominate the cellular picture in the anterior lobe at 498 hours of development.

From 388 through 450 hours of incubation the acidophils seem to have reached the peak of granular accumulation. Hyperactivity of the embryonic acidophils appears to be accompanied by pyknotic changes in the nuclei. Aron (5) found that a similar pyknotic occurs following hyperactivity of embryonic acidophils in the sheep. Just why the acidophils first arise in the anterior lobe and then differentiate posteriorly is not known. It seems to be a fact that the embryonic pars glandularis and pars tuberalis have, early in the incubation period, the potentiality for acidophil development; this becomes limited to rather definite regions at about hatching time and later.

Basophilic cells appear at about the same time as the first acidophils, but as Rahn (111) has stated, fully mature basophils are not seen until several weeks after hatching. Basophils decrease in number as the development periods progress. During much of the development period the basophils are scattered throughout the pars glandularis. From 450 hours of incubation to hatching, the basophils seem to be limited to rather definite regions. At 498 hours there is a rough separation of the anterior lobe into

two cellular zones, of which the postero-central area contains a preponderance of basophils, and the antero-peripheral area consists of mostly lightly staining acidophils. A similar zonation has been described by Schooley and Riddle (129) for the pigeon, but Rahn (111) stated that there is no evidence of this zonation in the chicken. No evidence is found for a central acidophilic and a peripheral basophilic area as reported by Tilney (149). The only peripheral area containing a preponderance of basophils is the region of original attachment of the hypophysial stalk.

In the mammalian hypophysis the residual lumen marks the anterior boundary of the pars intermedia. In the chick at 165 hours of development, (Fig. 3) the residual lumen begins to break up, primarily because of growth. By 272 hours the residual lumen has become fragmentary. This, of course, makes it difficult to locate the pars intermedia. Müller (96) was the first to note the regression of the lumen at twelve days. Similar observations at ten days have been made by Ezomo (34), who further recorded a complete disappearance at fourteen days. Tilney (150) described a residual lumen in the adult chicken. It would appear, from his description, that he was referring to a space between the pars glandularis and the pars tuberalis. Stendell (140) stated that a pars intermedia has been found in the domestic fowl. Herring (54) and De Beer (28) found that the residual lumen is absent in the adult.

The pars intermedia in higher vertebrates serves as a connecting structure between the pars glandularis and the pars nervosa. In the chicken a connective tissue sheath separates the posterior lobe of the pars glandularis



from the pars nervosa. (Fig. 7, 8). Müller (96) described connective tissue cells which separated the hypophysial lobes. Early in development the posterior lobe is in contact with the infundibular process, (Fig. 3), but after 272 hours no contact between the two components was observed. (Fig. 5). Economo (34) has made similar observations. In the pigeon, according to Schooley and Riddle (129), a fibrous capsule separates the two hypophysial components. Rahn (111) stated that contact frequently exists between some of the infundibular diverticula and the pars glandularis up to the eleventh day of incubation. The pars intermedia then, cannot be recognized by studying the topographical arrangement of the lobes of the hypophysis.

Even the cytological analysis of the hypophysis reveals no typical pars intermedia. Rahn (111) found that the cytology of the juxta-neural area reveals a few special cell cords which appear after hatching. These cell cords are made up of chromophobe and acidophil cells. The only evidence favoring the interpretation that this region is the pars intermedia is the presence of chromophobes. The presence of acidophils would indicate that the region is typical posterior lobe tissue, since Rahn (111) stated that these cell cords pass into the pars glandularis. Cell cords typical of Rahn's description have been found in later stages of development in the pars tuberalis. Siler (132) and Poris (107) have found that the acidophils compose part of the cellular elements of the pars intermedia of reptiles. Collin (20) and De Beer (28) found no cytological

evidence for the presence of a pars intermedia in chickens. De Lawder, Tarr and Gelling (30) found a small area of cells corresponding to the pars intermedia in the posterior pole of the pars anterior of the chicken. Rahn (110) stated that morphologically "there is no evidence for a pars intermedia, though in a corresponding region the cytology reveals a few cell cords which can be variously interpreted." This study reveals no cell cords which can be interpreted as pars intermedia tissue. Haller (50) and Herring (54) illustrated a structure in the chicken which must be interpreted as pars tuberalis and which they regarded as pars intermedia. Tilney (150) located a pars intermedia in the region of the pars glandularis, lying nearest to the infundibular process. From a cellular description of this area, and from his reconstruction, this seems to be confused with the posterior lobe of the pars glandularis.

To briefly summarize the evidence accumulated, it may be stated that a typical, differentiated pars intermedia is absent in the chick embryo. To further substantiate this statement from a physiological point of view, De Lawder, Tarr and Gelling (30), Kleinholz and Rahn (70), found that a chromotopore-expanding principle is present in the pars glandularis of the chicken. Kleinholz and Rahn (71), pursuing the problem further, found that the cephalic-third of the pars glandularis contains twenty times more intermedia than the caudal-third, while the middle-third lies between these two in potency. From these results it is concluded that intermedia is produced by the light staining acidophils.

A recent investigation by Rahn and Painter (112) stated that there is no evidence for a pars intermedia in the chicken.

The observations reported by Atwell (7) on the pars nervosa agree with those made in the present study (Fig. 7, 8) in that the lobe proper is irregular in outline because of numerous protuberances and separated from the pars glandularis by a connective tissue layer.

#### Glandula thyreoideae

The observation that the entire thyroid primordium of the chick develops from an unpaired median ventral invagination of the pharyngeal epithelium, (Fig. 9), agrees with the view held by Remak (118), Mall (85), Verdun (154), and Marine (87). This invagination occurs in the region of the first branchial cleft, and as development proceeds, the thyroid primordium migrates posteriorly with the aortic arches to a final intrathoracic position. During early development the thyreo-glossal duct and isthmus disappear. This view of the development of the thyroid does not agree with that held by Stieda (141) who stated that the gland has a lateral, as well as a median, origin. Mall (85) designated the derivatives of the fourth visceral pouch as "Korpern Y", and concluded that they do not participate in the development of the thyroid. The present study agrees with Mall's conclusion.

The age at which the thyroid primordium first appears varies among the embryos examined. All of the embryos show thyroid primordium at 40 hours of development. This observation is supported by the reports of Lillie

(79), Yoshikawa (174), and Bradway (15); they stated that the thyroid anlage first appears at 33, 42, and 54 hours respectively.

The thyroid primordium loses connection with the pharynx at 96 hours of development. This observation is in agreement with that of Lillie (79). Yoshikawa (174) found that the thyroid anlage loses connection with the pharyngeal epithelium by 72 hours. On the other hand, Bradway (15) observed that the thyroid anlage loses pharyngeal connection at 120 hours. This seems to be very late, and does not agree with the above observation that the gland becomes completely paired at 120 hours.

The first indication of pairing of the thyroid gland occurs at 110 hours of incubation; (Fig. 10). complete pairing takes place at 120 hours. (Fig. 11). This observation agrees exactly with that of Bradway (15), and of Yoshikawa (174). Verdun (154) stated that complete pairing of the gland does not occur before 172 hours; this is in agreement with Lillie (79) who found that complete pairing occurs at 168 hours of incubation.

Clearly-defined non-follicular spaces are observed at 148 hours. This agrees fairly well with the work of Bradway (15) and Yoshikawa (174) who stated that the thyroid gland acquires non-follicular cavities at six days, and at five and one-fourth days respectively. It was observed that at 165 hours the plates of epithelial cells, separated by non-follicular spaces, become distinctly visible. (Fig. 13, 14). Slight variation exists between the results of Bradway (15) who stated that epithelial cell plates become visible at eight days, Yoshikawa (174) who found epithelial plates formed

between five and one-half and eleven days, and Sun (142) who reported visible epithelial plates at six days.

Intracellular chromophobic colloid appears at 240 hours (Fig. 15, 16) and the first primary follicle at 260 hours. At this time many of the cells contain chromophobic colloid. Bradway (15) observed colloid for the first time at eleven days, and follicular formation at thirteen days. This observation agrees with that of Yoshikawa (174) who observed colloid at eleven and one-half days. Hopkins (62) found chromophilic colloid in the ten-day embryo. Physiological studies by Sun (142) indicated that the active principle of the thyroid is detectable in the thyroid at ten days, and thereafter increases in both relative and absolute amounts.

The first colloid secreted is chromophobic in nature. (Fig. 18). This agrees with the conclusions of Bradway (15), and Yoshikawa (174). Hopkins (62), on the contrary, stated that chromophilic, rather than chromophobic, colloid is first formed. All investigators agree that the colloid is first observed intracellularly. The colloid in the follicles of the 284-hour thyroid gland has a tendency to stain chromophilic, but does not become definitely chromophilic until 295 hours. (Fig. 19). Bradway (15) found that the colloid of the thyroid of the twelve-day chick, which had previously been chromophobic, is chromophilic.

The primary follicular cavities are formed by secretion and coalescence of the chromophobic colloid which has its origin near the nucleus of the follicular cells on the side next to the future lumen of the follicle. Growth of the follicles is achieved by a fusion of the follicular

epithelium with cells which have not yet organized into follicular formation. Occasionally a follicular epithelial cell is found in a state of mitosis; this may account for some of the follicular growth. Bradway (15) is of the opinion that follicles become larger by proliferation of follicular cells and consequent addition to the stored colloid. Further, Bradway found that growth of follicles by fusion of follicles, and multiplication by budding, takes place only in very rare instances. Yoshikawa (174) found that interfollicular epithelial cells form new follicles.

Different cells in the same follicle secrete either chromophobic or chromophilic colloid at the same time. This observation was first made at 295 hours. Bradway (15) made a similar observation. No cells were found to contain both chromophobic and chromophilic colloid at the same time as was noted by Hopkins (62).

When chromophobic colloid is present in a follicle which contains chromophilic colloid, the follicular colloid gives the impression that vacuoles are present. (Fig. 22). Therefore, the so-called vacuoles which have been described in the thyroids of various animals are probably chromophobic colloid. Because of the increased secretion of droplets of chromophobic colloid in the late embryonic stages, it is thought that the function of this colloid is to dilute the more dense chromophilic colloid.

The method by which the follicular contents reach the circulatory system is controversial. Hopkins (62) described definite single, tube-like openings leading from the lumina of follicles to the surrounding

circulatory spaces. She believed that such an opening is functional during each functional cycle of a follicle, and thereby furnishes a route by which the colloid reaches the circulatory system. The evidence presented by this investigation shows that these so-called openings are not true openings. (Fig. 31). Upon careful examination it can be seen that they are cells filled with colloid. The surface of the cell nearest the lumen of the follicle is not intact, and the cell is not degenerating; the nucleus appears normal as compared with other follicular nuclei. As a result, colloid seems to push through the cytoplasm to the base of the cell which usually borders a vascular space. The appearance now is that of colloid passing directly from the lumen of the follicle to a vascular space. There is, however, a basement membrane which prevents the passage of the colloid directly into the vascular system. In no case did colloid stream from the cell into a vascular space. Therefore, it is believed that the active principle of the thyroid follicle reaches the circulatory system by physicochemical processes through the basement membrane, which is formed from the endothelial lining of the vascular spaces.

The follicular epithelial height was found to vary only slightly during the developmental stages of the chick. The follicular diameters show some significant variability. The maximum diameter attained during embryonic development, for a single follicle, was 30 microns. There is a progressive increase in the mean follicular diameter from 295 hours to hatching. (Figs. 16, 18, 19, 21, 22, 25).

Glandula parathyroideae

The fact that the parathyroid glands are derived from visceral pouches III and IV is not verified by this investigation. Lillie (83) does not describe the parathyroid glands, but he does mention epithelial vestiges from visceral pouches III, IV and V. Verdun (154) found that the ventral surface of pouch III develops an epithelial node whose structure and evolution is similar to that of the parathyroid glands of mammals.

The parathyroid glands develop along with the thyroid glands. The parathyroid primordia evaginate with the thyroid from the floor of the pharynx and migrate posteriorly with the thyroid primordia. At 148 hours a lobe, lateral to each thyroid is pinched off. (Fig. 12). At 165 hours a small group of cells is separated from the anterior lobe of the parathyroid. These cells will become the small posterior lobe of the parathyroid. (Fig. 13).

The parathyroid glands do not develop as a spherical mass of cells. Following differentiation the cells form a crescent-shaped epithelial cord, which branches as the gland develops. (Figs. 14, 17). Nonidez and Goodale (98) stated that the cords of parathyroid cells, when fully developed, are directed toward the center of the gland. This interpretation is incorrect, since the cords of parathyroid cells develop away from the center of the gland.

The lobes of the parathyroids develop unequally in size. The first mass of cells which is detached from the thyroid tissue becomes the larger



of the two lobes. The small group of cells detached from the anterior lobe becomes the smaller, posterior lobe. The larger parathyroids are usually found almost in contact with the posterior pole of the thyroid lobes.

Nonidez and Goodale (98) mentioned that there are instances in which this position is reversed. No cases of this reversal of position were observed during this investigation.

In addition to the main parathyroid glands there may occasionally be found masses of accessory parathyroid tissue which occupy varying positions. A similar observation was made by Nonidez and Goodale (98). Accessory parathyroid tissue and thymic tissue have been found embedded in the posterior lobes of the thyroid, and in the ultimobranchial bodies which are situated in the loose connective tissue in the space between the carotid artery and jugular vein. Verdun (154) has shown that the ultimobranchial bodies, formerly regarded as the "lateral" lobes of the thyroid, arise from a fifth pair of rudimentary pharyngeal pouches. From the material used in this investigation it appears that the ultimobranchial bodies develop from the floor of visceral pouch IV. Much variation occurs in the development of these bodies. In some embryos they were well developed, while in others, only a small mass of cells could be found. Without the aid of serial sections many of the ultimobranchial bodies would go unnoticed.

The presence of thymic and parathyroid tissues in the same organ is explained by the fact that as the thyroid and parathyroid cells lose connection with the pharyngeal epithelium, some of the cells from the third and

fourth visceral pouches are carried posteriorly in the migratory process, and become differentiated later in embryonic life.

Nonidez and Goodale (98) explained the presence of thymic and parathyroid tissues in the same organ by the fact that, since the ultimobranchial bodies represent remnants of rudimentary pharyngeal pouches, a complete separation of the thymic and parathyroid anlagen, such as normally occurs in the third and fourth pairs of pouches at earlier stages of development, has not occurred.

The presence of parathyroid tissue in the ultimobranchial body would mean that a few cells from the parathyroid anlage were carried down with the fourth visceral pouch when it separated from the pharynx. That is, as the thyroid and parathyroid anlagen separate from the pharynx, a few cells from the parathyroid anlage remain in contact with the fourth visceral pouch, since this pouch does not lose connection with the pharynx until 134 hours of incubation. The thyroid and parathyroid lose connection with the pharynx as early as 96 hours.

The first noticeable change in the cells of the parathyroids, on differentiation, is a decrease in nuclear chromatin and an increase in cell cytoplasm. This change occurs at 260 hours, and is followed at 272 hours by an acidophilic staining reaction of the cytoplasm. Blood vessels first invade the glandular parenchyma at 295 hours. At the same time chromatin material in the cell nuclei begins to increase and the cytoplasm continues to become more acidophilic.

At 400 hours the three cell types which are present seem to be similar to those described for mammals. The first type is known in mammals as the clear chief cell, the second, as a small dark chief cell (Petersen, 102; Getzowa, 44; Noodt, 99), and the third type, as a large bright oxyphilic cell (Welsh, 159).

The clear or chief cells vary in number throughout the incubation period, and at hatching time are scattered throughout the glands. The small dark chief cell, which is the predominant cell type, is intermediate between the clear chief cell and the oxyphil cell. The oxyphil cell appears late in embryonic life, and is found singly or in groups, with the largest number confined to the periphery of the gland.

#### Thymus

After 120 hours of incubation it is possible to observe the double origin of the thymus. (Fig. 26). The large portion or thymus III, is derived from the ventral and lateral wall of the third visceral pouch. This observation is not in agreement with that of Verdun (154) and Lillie (79) who find that thymus III is derived from the dorsal wall of the intermediate part of the third visceral pouch. Thymus IV, a smaller portion than thymus III is derived from the dorsal wall of the intermediate part of the fourth visceral pouch, and eventually fuses with thymus III. This observation has been made previously by Verdun (154) and Lillie (79).

The third and fourth visceral pouches sever their connections with the pharynx by 134 hours of incubation. Verdun (154) observed that the

fourth cleft was separated from the pharynx at 164 hours of incubation.

At 165 hours large lymphocytes are scattered here and there throughout the mesenchyme and especially around the blood vessels of the neck, and upper thoracic regions. (Fig. 27). After 177 hours an occasional large lymphocyte migrates into the periphery of the epithelial thymic tissue from the surrounding mesenchyme.

Irregular lobules form in the thymus as a result of growth of the epithelial cells. (Fig. 29). Connective tissue ingrowth from the primitive capsule, coupled with growth and increase in number of the epithelial cells, produces the primary lobules. The ingrowths of connective tissue from the capsule mark the beginning of the thymic stroma. The lobules are widely separated in early embryonic life by loosely arranged cellular connective tissue. As the rate of growth of the thymus increases, the lobules become intimately associated and compress the connective tissue stroma into thin septa late in embryonic life. The interlobular septa, as a rule, do not penetrate the parenchyma except for thin strands accompanying blood vessels. All blood vessels are contained in the stroma. Many cellular elements are always present in greater or less numbers in this stroma. The formation of lobules begins after 213 hours of incubation at the cephalic end of the thymus. It is not until after 228 hours that the thymic lobules form in the mid-cervical and thoracic regions. At this period there are no blood vessels in the thymus. Small thymic cells are beginning to appear in the mesenchyme surrounding the thymic anlage.

After 252 hours both large and small lymphocytes are rather prevalent in the thymic primordium. Blood vessels are numerous in the interlobular septa, but do not appear in the thymic tissue. Many mitotic figures are present among the large lymphocytes and epithelial nuclei. At this time the largest number of lymphocytes are found in the interlobular septa. It is concluded from this that the lymphocytes, which are present in the surrounding mesenchyme of the thymus migrate into the thymic tissue along the interlobular septa. Since there are no transitional forms between the epithelial cells and lymphocytes, and since blood vessels are absent in the thymic anlage, it is concluded that the first source of lymphocytes in the thymus is a result of their migration from the surrounding mesenchyme.

The small lymphocytes arise from the cellular division of the large lymphocytes. This fact is based on the following: There are no blood vessels present in the thymic parenchyma at this period; transitional cell forms between epithelial cells and lymphocytes are absent; the lymphocyte series consists of large, intermediate and small stages; frequently mitoses are present among these lymphocytes.

Between 260 and 295 hours there is a marked decrease in the number of lymphocytes in the thymus. During this time, however, small blood vessels appear in the thymic parenchyma and an epithelial syncytium forms about the periphery of the thymus. Also during this period embryos were observed in which the thymic tissue had grown posteriorly between the jugular vein and thyroid, terminating in the space between the posterior pole of the thyroid

and the parathyroid glands. This has been previously observed in adult chickens by Greenwood and Blyth (49).

After 295 hours large numbers of the lymphocyte series are again present in the thymus, particularly around vessels within the parenchyma near the periphery, and in the interlobular connective tissue. The periphery is rather compact as contrasted with the central portion of the lobules, which are composed primarily of loosely arranged epithelial cells. This is followed by an increase of small thymic cells in the periphery.

After 319 hours well-developed cortical and medullary zones are distinguishable, (Fig. 29), but it is not until after 357 hours that a distinct and definite separation of the two zones can be made. (Fig. 31, 32). Sun (142) has made a similar observation.

The medulla develops from the epithelial syncytium of the thymic primordium. The epithelial or reticular cells are clearly demonstrable in the cortex at 345 hours. Very few lymphocytes are present in the medullary zone when both the cortex and medulla become definite. Development of the cortical reticulum is gradual. Prior to 357 hours the syncytial network in the medulla and cortex is coarse. After the cortical and medullary zones become definite, the coarse syncytial network of the previous stages changes gradually to a fine reticulum.

After 319 hours a few of the epithelial cells are organized into groups of two or three cells which have extremely large nuclei. These groups of cells mark the beginning of the formation of Hassall's corpuscles. These

bodies vary in size and number as embryonic growth progresses toward hatching. At 450 hours the typical Hassall's corpuscles have diameters varying between 30 and 40 microns. (Fig. 31).

As the medulla becomes well-developed the number of lymphocytes within this zone is less. (Fig. 32). However, all three sizes of lymphocytes are present in the medulla throughout its development. The apparent disappearance of lymphocytes from the medulla, as development progresses may be attributed to one of the following conditions: The lymphocytes may migrate from the medulla into the cortex. The increase in volume of the medulla, produced by the increase in epithelial cells, may spread the lymphocytes of the medulla over a larger area. Thus, there may be a scattering, but no decrease in the number of lymphocytes. The third interpretation is made on the basis of the blood supply to the thymus. The arteries are distributed in the cortical zone of the lobules through the cortical stroma. Here the arteries break up into a capillary network which converges toward the venous vessels of the medulla. On the basis of this vascular arrangement it may be possible for the lymphocytes to migrate from the cortex to the medulla where they enter the venous capillaries, and are carried into the general circulation.

After 400 hours free erythrocytes and eosinophiles are present in rather large numbers. It is not until late embryonic life that the eosinophiles become numerous. There may be a correlation between the presence of free erythrocytes and eosinophiles, since they never occur alone. The eosinophile cells, in general, are more numerous in the connective tissue of the inter-

lobular septa than in the lobules of the thymus. Within the thymic lobule they are more numerous in the medulla than in the cortex. Eosinophiles are present in appreciable number within the thymus throughout the last four days of the incubation period, but the number within the thymus at any one time is variable. Most of the eosinophiles are of the polymorphonuclear type.

Other cell types appear in the thymus during the closing hours of incubation. Many erythroblasts are present at 426 hours. Occasionally multinucleated giant cells are found in the cortex after 450 hours. It is believed that these cells play a phagocytic role in the late stages of the incubation period. Degenerate cell products would be phagocytized by these giant cells.

In many of the embryos after 400 hours cystic spaces are present in some of the thymic lobules just above the anterior pole of the thyroid. The spaces are lined with a simple squamous to cuboidal epithelium, and they vary in size and number in the different thymi. All of these spaces lie within the thymic lobule. When these thymi are traced through serial sections the cystic spaces usually end blindly, but occasionally they end as solid epithelial nests which appear to be continuous with the reticulum.

These cyst-like spaces may arise from the failure of the original thymic tubule to lose its lumen, or from the rapidity with which the thymus grows.



Glandula suprarenalis

The cells of the cortical primordia of the adrenal gland first appear between 90 and 96 hours of incubation. This observation has previously been made by Hays (53), and Willier (167). These cells are derived from the medioventral coelomic epithelium over the anterior pole of the mesonephros. This observation is in agreement with that of Soulie (137), and Hays (53).

Between 110 and 120 hours of incubation, large oval cells migrate ventrally from the primary sympathetic trunks on either side of the dorsal aorta. These sympathetic cells, as they approach the cortical cells, migrate between them and are found deeply in the cortical tissue at 134 hours. They give rise to the chromaffin tissue in the adrenal glands. This observation substantiates the work of the majority of investigators (Fusari, 42; Soulie, 137; Hays, 53; Rau and Johnston, 115; and Willier, 167). Those investigators not in agreement have been cited in the literature review.

After 148 hours masses of sympathetic cells appear along the dorso-medial surfaces of the adrenal glands. These sympathetic cell masses consist of two types of cells, ganglionic and non-ganglionic cells, which arise from the secondary or definitive sympathetic trunks. Prior to this time the sympathetic cells are derived from the primary sympathetic nerve trunks. Both of these cell types migrate into the adrenal tissue at 165 hours.

Most investigators are of the opinion that the non-ganglionic cells are of ectodermal, rather than mesodermal, origin. The present study agrees with this observation. However, in this study no intermediate cell stages are found between the ganglionic and non-ganglionic cells developing into chromaffin tissue. So far as the author is aware no description of such cellular transformation occurs in the literature. It is interesting to note that the chromaffin cells resemble the non-ganglionic cells except that they possess more granular cytoplasm. Perhaps the non-ganglionic cells differentiate into chromaffin cells after they migrate into the adrenal tissue. The non-ganglionic cells are more numerous than the ganglionic cells which is also indicative that they may change into chromaffin tissue. However, there seems to be more indirect evidence to substantiate the hypothesis that the ganglionic cells produce chromaffin tissue than that the non-ganglionic cells produce it. As development of the adrenal gland progresses, the number of ganglionic cells decreases. These cells are usually confined to the periphery of the gland. Near the close of the incubation period the greatest portion of chromaffin tissue is also confined to the periphery of the gland. (Fig. 38, 39). Therefore, it is assumed that because the ganglionic cells decrease in number within the gland, and are confined to the periphery, and because most of the chromaffin tissue is located in this area, the ganglionic cells are responsible for chromaffin cell formation

Willier (167) also obtained evidence that supports the above hypothesis. Willier found that "a suprarenal forms in the graft from a wolffian body

isolated from a four-day embryo, two days before the secondary sympathetic nerve trunks begin to form." From the observations made in this study the non-ganglionic cells are not distinguishable until 148 hours. Therefore, it may be assumed that the ganglionic cells are transformed into chromaffin tissue. Willier, however, points out that the secondary sympathetic cells may contribute indirectly to the formation of the medullary cords. Poll (105) thought that cells from the primary sympathetic system are responsible for innervation to the adrenal glands. Goormaghtigh (45) considered these cells essential for nerve supply and for the production of chromaffin tissue.

Therefore, the exact origin of the chromaffin cells is still unknown. There is evidence that both the ganglionic and non-ganglionic cells may be transformed into chromaffin cells. If the ganglionic cells are the sole source of chromaffin cells then perhaps the non-ganglionic cells serve as supporting cells. Perhaps the medulla is composed of chromaffin cells which have nervous connections and are essential in the production of epinephrine, and cells which are not. In this case it may be plausible to assume that the ganglionic cells give rise to the chromaffin cells which produce epinephrine, while the non-ganglionic cells produce chromaffin tissue which is not secretory in nature. However, in this connection two types of chromaffin cells can not be distinguished. Furthermore Sun (142) has found that, as the chromaffin tissue increases, so also the epinephrine content of the glands increases.

The time of penetration of the sympathetic cells into the adrenal glands varies according to the investigator. Fusari (42) found sympathetic

cells among the cortical tissue at the end of the fourth day. Rabl (109) and Soulie (137) observed sympathetic cells, contiguous with the cortical primordium, at the end of the fourth day. From the sixth to the ninth days these investigators observed that the sympathetic cells formed a ganglionic mass on the medio-dorsal face of the cortical tissue. From this ganglionic mass, sympathetic medullary cells began to penetrate the cortical cords on or about the eighth day. Willier (167) is of the opinion that in a graft from a four-day embryo, "the primary sympathetic cells contiguous with the cortical primordium multiply to form a mass before any cells separate and penetrate as medullary cells between the cortical cords." The present study indicates that sympathetic cells migrate into the adrenal glands from 110 hours until hatching. It is evident from this observation that the migrations of sympathetic cells into glands occurs in waves throughout the incubation period. During the early stages of development the sympathetic cells migrate between the loosely arranged cortical cords. After a definite capsule is formed the cells migrate into the gland along nerve fibers. Rabl (109) stated that penetration of sympathetic cells is still evident in a sixteen-day embryo. Wiesel (160), working with human material, found sympathetic cells migrating into the glands until at least the tenth year.

The relationship between chromaffin and cortical cells is interesting. The chromaffin cells are found between the cortical cords and are associated with the sympathetic cells which are found within the gland or con-

tiguous with the surface of the gland. The sympathetic cells are not found in contact with the cortical cells, but only with chromaffin cells and connective tissue. Connective tissue separates the chromaffin and sympathetic cells from the cortical cells. Furthermore, chromaffin cells are always in contact with a venous sinusoid. These relationships suggest that the sympathetic cells differentiate into chromaffin cells. Just what influence stimulates the change of sympathetic cells into chromaffin cells is unknown. From casual observation one might assume that the cortical cells stimulate the transformation of cells into chromaffin tissue. However, this does not explain the production of chromaffin cells outside of the adrenal glands. As noted above, masses of ganglionic tissue containing ganglionic, non-ganglionic, and chromaffin cells are located outside the adrenal glands during the developmental period and at hatching time. These ganglionic masses stimulate paraganglia.

A morphological study of the developing adrenal glands does not answer the question as to what role the sympathetic cells play in the differentiation of the cortical tissue. There is no evidence that the differentiation of cortical tissue is dependent on sympathetic cells.

#### Indifferent Gonad and Ovary

The origin and migration of the primordial germ-cells in the chick is still a subject of considerable controversy. For this reason, and because that particular problem is so involved, the author decided not to include

experiments directly concerned with this phase of the investigation. For recent reviews of the subject the reader is referred to Heys (56), and Blocker (14). It is a generally accepted view that the primordial germ-cells are germinal in nature; however, many critical investigators have not yet accepted this view. Swift (144), and (145), and Goldsmith (46) have traced the migration of the primordial germ-cells into the developing gonad, and have followed the cytological changes into definitive sex cells. The work of Reagan (116), Benoit (13), and Deutschakoff (26) lends support to the view that the primordial germ-cells originating in the germinal crescent, are the forerunners of definitive sex cells. The work of these authors does not rule out the fact that some cells in the sterile gonad may later be able to form sex cells. Some evidence favoring this view has been presented by Fell (35), and Gatenby (43). They showed that the germ-cells may arise from the peritoneum of the adult fowl. Firket (36), and (37) presented a not too convincing argument for the existence of two sets of germ-cells. He believed that the first, or primary, set degenerates and is replaced by germ-cells which originate from the epithelial elements of the gonad. It is also possible that the definitive sex cells may arise from both these sources.

Assuming the extra-gonadal origin of the primordial germ-cells, Brode (17) observed that in the chick they persist in the right ovary prior to the third week, after which time they gradually disappear. Benoit (12), and Donn (31) found that if the left ovary is removed from the chick before

the time of the primordial-germ-cell disappearance, the right rudimentary gonad would transform into a testis containing male sex cells. On the other hand, if the left ovary is removed after the disappearance of the primordial germ-cells from the right rudimentary gonad, no sex cells differentiate in the testis. These experiments are the most conclusive evidence that the primordial germ-cells are the sole source of the definitive sex cells.

Von Berenberg-Gossler (156) believed that the primordial germ-cells are non-germinal in character. His researches confirmed, in all essential points, Swift's account of their origin and migration to the genital ridge. He regarded them as entodermal wandering cells which later transform into mesodermal cells; since these cells are similar to other mesodermal cells, they may give rise to sex cells. This view is not widely accepted.

The present investigation was conducted under the assumption that the primordial germ-cells have an extra-gonadal origin. The observations made on the origin and migration of the primordial germ-cells agree fairly well with those made by Deutschakoff (24), and Swift (143). According to Deutschakoff the primordial germ-cells are distributed in the embryo and vascular area until the 22-somite stage, at which time they have entirely disappeared. Swift, on the other hand, found all the germ-cells together with the blood elements in the blood vessels up to the 21-somite stage; after this time they gradually disappear and are absent after the 25-somite stage.

In the 96-hour embryo the single layer of epithelium covering the gonad is called the germinal epithelium; it was first described in the

chick by Waldeyer (158). At 96 hours the left gonad is larger than the right. Swift (144) stated that the "left gonad is more massive than the right" in the 90-hour embryo. In this connection Pirket (36) mentioned the unequal distribution of the primordial germ cells in the gonads of a four and three-fourths-day embryo. He counted approximately 750 gonocytes in the left, and 150 in the right gonad. Swift (144) counted about twice as many in the left as in the right, in one four-day embryo, while in a second embryo they were five times more numerous in the left gonad. Dantschakoff (26) stated that at the 24 to 26 somite stage the left side contains rarely less than twice, and generally three to five times, as many as the right side.

The observations made in this investigation do not conform with the account of Dantschakoff (26). The germ-cells in the gonads investigated are nearly evenly distributed up to the end of the third day of incubation. This observation agrees with that of Witschi (170). During the fourth day of development this investigation revealed that the left gonads contain approximately 70 per cent, while the right contain 30 per cent, of the total germ-cells counted in the gonads of four embryos. (Table 2 ). At this stage the mesentery forms between the gonads by the inward movement of the splanchnopleures which fuse. These splanchnopleures contain germ-cells, and this accounts for the rather sudden unequal distribution of the germ-cells. According to Witschi (170), immediately after mesenteric formation there is a "passage of more than half of the germ-cells from



the right to the left side." Swift (144) expressed the opinion that the "unequal distribution of the germ-cells in favor of the left side may account for the fact that the gonad of that side is, from its first appearance, the more massive." The unequal distribution of germ-cells between the two gonads is rather definite proof that they migrate and are not distributed by tissue displacement as Von Berenberg-Gossler (156) advocated.

By 120 hours there is a demonstrable difference in the thickness of the germinal epithelium between the left and right gonad. (Fig. 40). The germinal epithelium covering the left gonad is approximately twice as thick as that of the right. There seems to be a direct proportion between the number of germ-cells present in either gonad and the thickness of the germinal epithelium. This observation lends support to Swift's statement above, relative to the differences in size between the two gonads. In this connection it is also interesting to note that the stroma of the left gonad is approximately twice as thick as that of the right.

Occasionally, at the 120-hour period, a narrow cord is found to extend obliquely toward the medial surface of the mesonephros. This cord of urogenital union is characterized by a condensation of mesenchymal tissue. According to Firket (36) there are sixteen of these cords and they, together with the tissue under the germinal epithelium, make up the urogenital connections or "organ of Mihalkowics" as described by Sainment (126). There are differences of opinion with regard to the origin of these cords of urogenital union. The findings in this investigation agree with those

of Firket (36), and Swift (144), who stated that they arise from mesenchyme. However, Sainmont (126) believed that in the cat, these cords arise from the epithelium of Bowman's capsule. Allen (3), working with reptiles, described them as derived through invaginations of the germinal epithelium. From the above observations it is noted that the cells making up the cords of urogenital union have all the characteristics of mesenchymal cells, and that they blend with other mesenchymal cells under the germinal epithelium. The cells do not resemble the elongated prismatic cells of the germinal epithelium, nor the flat simple squamous cells of Bowman's capsule. The cords were not counted because some of them were very indefinite.

A marked change occurs in the gonads between 134 and 165 hours. (Fig. 41). The sexual cords of first proliferation are best seen at this period. Swift (144) observed the period of first proliferation of the sexual cords between 132 and 156 hours. At 165 hours of development the formation of cords of first proliferation has ceased. According to Swift (144) these sexual cords cease forming abruptly at 156 hours. The sexual cords are destined to form the seminiferous tubules in the male and the medullary cords in the female.

At 165 hours morphological sexual differences appear in the gonads. Prior to this time the gonads have shown no structural sex differences. The indifferent period extends from the time of origin of the gonad as a genital ridge, to the time of sex differentiation which, in the material studied, is approximately 165 hours. Swift (144) observed that at about 156 hours of development the sex of the individual could be definitely

determined.

Several criteria are helpful in the determination of sex at 165 hours. These have already been noted by Swift (144) as differences in relative size of the right and left gonad, thickness of the germinal epithelium, size of the cells in the germinal epithelium, and the number and size of the primordial germ-cells.

From the time of the indifferent stage of development, the left gonad has been larger than the right. However, at 165 hours the difference in size between the left and right female gonads is more striking. In the male this difference in relative size between the two gonads is not marked, but the left gonad is slightly larger than the right. The difference in relative size between the gonads in the female is produced by the rapid growth of the cords of first proliferation, and the constant increase in thickness of the germinal epithelium covering the left gonad.

The germinal epithelium of the left gonad of the female is much thicker than the germinal epithelium covering the left gonad of the male at 165 hours. (Fig. 42, 43). The thin germinal epithelium covering the right female gonad is similar to that covering the right and left gonads of the male. This difference in thickness of the germinal epithelium is the result of several factors. As previously pointed out there seems to be a direct correlation between the number of primordial germ-cells present in the gonad and the thickness of the germinal epithelium. Thus, as the number of primordial germ-cells increases, so also the thickness of the epithelium

increases. Another factor contributing to the thickness of the germinal epithelium is the size of the cells. The cells are taller in the epithelium of the left gonad of the female than in the epithelium of the right gonad and that covering the testicles.

At 165 hours primordial germ-cells are numerous in the left gonad of the female, and they are larger than those in the male. Only an occasional primordial germ-cell is present in the germinal epithelium of the male gonad. Apparently all these cells have migrated into the sexual cords.

Prior to 191 hours there has been no evidence of cellular division of the primordial germ-cells. This stage marks the beginning of a period of rapid proliferation of the germ-cells which reaches its peak between 213 and 228 hours. This observation agrees with that of Swift (144).

By 213 hours the germ-cells have increased in such numbers that the lower part of the germinal epithelium next to the medullary albuginea and medulla begins to take on a lobulated appearance. (Fig. 44). This observation has already been made by d'Hollander (29), Firket (36), and Swift (144). These lobulations of germ-cells are the beginnings of the cortical cords, or the cords of second proliferation, first described by d'Hollander (29), and Firket (36). It is at this time that the left gonad of the female becomes definitely differentiated into a cortex and medulla.

The medulla of the left ovary is well-developed at 213 hours, and medullary cords are lengthening, and developing lumina. (Fig. 44). No cellular divisions have been noted in the primordial germ-cells of the medulla prior to this time. The rapid increase in size of the left ovary

at this time, seems to be the result of the rapid growth of the medulla. After 213 hours, the right ovary consists primarily of medullary tissue. It is not until after 228 hours that the germinal epithelium covering the right ovary is completely reduced to a single layer of cuboidal cells.

At 240 hours, some of the germinative buds of the left ovary have become separated from the germinal epithelium by connective tissue. (Fig. 47). At 240 hours the right ovary is rapidly becoming rudimentary as compared with the left, and the epithelium is reduced to a single cell layer of flat mesothelium. (Fig. 46). The most striking feature of the right gonadal medullary zone is the large number of lumina in the medullary cords. It is apparent that the right ovary has a diminished growth capacity.

After 284 hours the germinal epithelium of the left ovary has been reduced to a single layer of cuboidal to columnar cells, an observation made earlier by Swift (144) for the fourteen-day chick embryo.

From 307 hours until hatching the anterior and posterior poles of the left ovary are the most active, since the cortical cords are consistently larger. (Figs. 50, 51, 53). The cortical cords, from this time until hatching, may be more massive and distinct in some embryos than in others. This variation in the massiveness of the cords within individuals, and between individuals, is perhaps the result of variation in blood supply. Some evidence to substantiate this belief has been presented by Willier (166). He attributed variations in the size of the cortex of grafted left ovaries to variable conditions of implanting, to the rapidity of incorpora-

tion of the implant by the chorio-allantoic membranes, and to the establishment of vascular circulation in the graft.

From 336 hours until hatching there is much variation in the size of the right ovary among individuals of similar age, and between individuals of different ages. This difference in size is dependent on the number and size of the distended medullary tubules.

#### Testis

A discussion of the indifferent gonad prior to 165 hours of development has already been presented. As mentioned above under the discussion of ovarian tissue, it is at 165 hours that morphological sex differences in the gonads become discernible.

The sexual cords, which begin to appear at approximately 134 hours, are the true seminiferous cords. As stated above these cords are homologous with the cords of first proliferation in the female. In the male there is but one series of cords, while in the female there are two.

Although the sexual cords begin to appear at 134 hours, it is not until 165 hours that the germinal epithelium reaches its greatest activity in their production. At the end of 165 hours of incubation the production of the sexual cords ceases. This point is reached at 156 hours according to Swift (144).

After 165 hours it is possible to distinguish between sexes microscopically. (Fig. 42, 43). The criteria on which this diagnosis is based

has been presented above. After 191 hours the sex of the individual can be easily ascertained, either with or without the aid of a microscope.

Seminiferous cords at 177 hours comprise most of the male gonads, since the germinal epithelium has been reduced to a single layer of cuboidal epithelium. The peritoneal cells are many times more numerous than the primordial germ-cells in the cords. In the male, as in the left ovary, there are more primordial germ-cells at the poles than in the center of the gonad. The primordial germ-cells of the male are slightly smaller than those in the left ovary, but they appear similar in structure.

It is not until 206 hours that the first primordial germ-cells are observed in cellular division. There is then a marked difference in the time at which the germ-cells in the male begin cellular division as compared to those of the female of a similar age. It should be recalled that during this period of development in the female the germ-cells are in an active mitotic phase, and the formation of the cortical cords is beginning to take place.

The amount of stroma between the seminiferous cords has greatly increased at 213 hours. (Fig. 45). This observation does not agree with that of Swift (145), nor Willier (166), who found that the stroma increased in the testes of the eleven-day embryo.

As the testes develop, the seminiferous cords become convoluted. Swift (145) has pointed out that this is the result of adaption by the cords to a space which grows more slowly. On the other hand, this is nature's method of increasing the surface of the seminiferous cords and

tubules and maintaining a small compact gland.

After 272 hours the arrangement of the peritoneal and primordial germ-cells is striking. Prior to this time the primordial germ-cells are scattered evenly throughout the cords. After 272 hours they seek a peripheral placement in the cords. (Fig. 52). Swift (145) also made this observation, but found this change in the placement of the germ-cells after the fifteenth day. Semon (130), and Popoff (106) observed that the primordial germ-cells have a definite position near the center of the seminiferous cord, while the peritoneal cells occupy the periphery.

It is of interest to note that at 272 hours the interstitial cells first appear in the stroma, and as development progresses, these cells become more numerous. Swift (145) records the presence of interstitial cells at thirteen days. The interstitial cells may be differentiated from the stroma connective tissue cells on the basis of intermediate cell stages among the connective tissue cells. These observations have previously been made by Swift (145). These interstitial cells vary in shape from round, or cuboidal to fusiform. The cell is easily differentiated from the ordinary connective tissue cell in that both the nucleus and cytoplasm stain deeply.

Seminiferous cords containing a discontinuous lumen begin to appear after 307 hours. Swift (145) reported cords containing a cavity in the twenty-day embryo. Semon (130) observed a lumen in some of the cords in the seventeen-day embryo. Thus the time at which the seminiferous cords first contain a lumen is variable, however, the lumina of the seminiferous



cords are not continuous at 498 hours. (Fig. 54). The seminiferous cords become truly seminiferous tubules sometime after hatching. The lumen results, as Swift (145) has pointed out, by a liquefaction of the cells in the central axis of the seminiferous cord; however, in most cases, it seems that a fissure appears between the cells and proceeds to enlarge.

#### Morphological and Functional Interrelationships

Since it has been established that the endocrine organs are essential for growth, an understanding of the morphological and physiological activities of these glands during the process of development of the embryo becomes important. The endocrine organs compose a system which functions as a regulator in maintaining a balance of the physiological processes of living protoplasm. In this discussion an attempt is made to correlate the morphological and known physiological activities of some of the developing endocrine organs.

With regard to the chick, Sun (142) has published the most extensive piece of work; this includes a morphological study of the thyroid, parathyroid, adrenal, and thymus glands, and a chemical study of the thyroids and adrenals from nine and one-half days until hatching. No attempt was made to determine the cytological significance or to trace the origin of the glands. The initiation and early development of the thyrotropic function in the developing chick embryo has been established by Martin-dale (88). Bradway (15) assumed that the glandular functioning of the

thyroid commenced after twelve days of incubation. Kleinholz and Rahn (71) have determined the distribution of the intermedin factor in the pars glandularis of the chicken hypophysis. Chen, Oldham and Gelling (19) detected a melanophore-dispersing hormone in the hypophysis of the chick at five days of incubation. Fugo (40) has developed a technique, and studied the effects of hypophysectomy in the chick embryo. This technique opened the way for a direct attack on the problem of endocrine relationships during early development.

During embryogeny the primordia of the glands of internal secretion appear at different times. The following table verifies this fact.

| <u>Gland</u> | <u>Appearance of Primordia in Hours</u> |
|--------------|---|
| Hypophysis   | 43 to 48                                |
| Thyroids     | 30 to 36                                |
| Thymus       | 110 to 120                              |
| Parathyroids | 148 to 165                              |
| Adrenals     | 90 to 96                                |
| Gonads       | 40 to 45                                |

Perhaps the early appearance of the hypophysial, thyroïdal and gonadal primordia may be attributed to their regulation of body growth and to their functional interrelationship.

The first hormone known to be produced by the developing glands is the melanophore-dispersing factor. Chen, Oldham and Gelling (19) have demonstrated this hormone in the hypophysis of the five day chick embryo. This observation is difficult to reconcile with an embryological and histological study of the hypophysis at this early period. In the first

place the hypophysis is not completely differentiated, and secondly the cells do not possess secretory granules in their cytoplasm. However, the distal end of the pars glandularis is somewhat enlarged at five days, and is slightly constricted from the buccal cavity. On the basis of this observation it may be assumed that the anterior lobe of the pars glandularis is responsible for the production of the melanophore-dispersing hormone. Snyder (135) has demonstrated the melanophore-expanding principle in the hypophysis of the Sus scrofa fetus before occurrence of the other hypophysial hormones. In this connection Maurer and Lewis (91) found that the melanophore-expanding principle could be present in the pars intermedia without the cells showing secretory activity. Therefore, it might be assumed that the melanophore-expanding hormone is stored during early embryonic life and liberated later, perhaps in the chick, after 462 hours or after the period at which the anterior lobe is completely differentiated.

Between 110 and 120 hours of incubation two marked morphological changes occur within the endocrine system. At this time the thyroid tissue becomes bilobed, and the medullary cells migrate into the cortical tissue of the adrenal glands. It seems doubtful that these two activities are dependent on one another.

After 134 hours of development the sexual cords make their appearance in the primitive gonadal tissue. Sexual cord formation seems to take place independently of other glandular activity. The work of Fugo (40) further substantiates this observation. Fugo found that sex differentiation is in-

dependent of hypophysis function.

Between 134 and 148 hours the anterior lobes of the parathyroid glands become separated from the thyroid lobes. The anatomical change seems to be independent of other glandular activity.

After 165 hours of incubation the posterior lobes of the parathyroid glands become detached from the anterior lobes. Sinusoids appear in the adrenal glands and development of sexual cords of first proliferation ceases. It is difficult to postulate an interrelationship between these glandular activities. However, the marked vascular growth in the adrenal glands is indicative of early function.

Between 165 and 177 hours, sex can definitely be determined. During the same period the large lymphocytes begin to invade the thymus primordium.

The cells of the pars glandularis of the hypophysis exhibit a general basophilic staining reaction at 191 hours. These cells, according to Rahn (111), differ from the future basophils and are considered as transitional forms. In the left ovary at this time, there is a marked increase in the number of primordial germ-cells in the germinal epithelium. It is generally recognized that the basophilic cells of the pars glandularis produce the gonadotropic hormone. On the basis of this knowledge, it seems plausible to suppose that if these embryonic basophils are producing hormone, the germinal epithelium of the left ovary would be stimulated to activity. It is difficult to justify this hypothesis when the histological picture of the testes is studied, since no activity is noted in the germ-cell-

producing tissues. The left ovary may be more sensitive to the gonadotropic hormone than the testis. Fugo (40) found that the germ-cell activity in the ovary and testis are independent of hypophysial activity. Riddle and Schooley (120) have found that in pigeons of less than 2.3 months, and in ring doves of less than 3.0 months, the production of follicle-stimulating hormone has not yet been initiated.

At 206 hours of development the basophilic character of the hypophysis is very pronounced. Small accumulations of colloid occur in the cytoplasm of many cells. This observation, coupled with the increased vascular development to the gland, might be considered indicative of function. At this period the adrenal glands have also become very vascular, and their chromaffin cells are situated next to the sinusoids. Therefore, if hormone is being produced by the hypophysis and adrenals, it could be made easily available for circulation.

The basophilic character of the hypophysis is maintained at 213 hours. A similar deep basophilic staining characterizes the cells of the thyroid and parathyroid glands. This deep staining is perhaps an indication that the cells will soon become secretory in nature. Further evidence that the hypophysis is now actively producing hormone occurs in the testes and ovaries. This evidence is based on the fact that the medullary cords of the ovary are rapidly increasing in length and exhibiting lumina, while the intertubular tissue of the testes is markedly increased. From the results obtained by Domm and Dennis (32) and Venzke (153) it is apparent that the

gonadotropic hormone stimulates the medullary portion of the embryonic ovary and the intertubular tissue of the embryonic testis. It seems that if there is gonadotropic hormone acting on the embryonic gonads, it produces an effect similar to that of the luteinizing hormone in mammals after birth. Fugo (40) observed that the cortex of both the hypophysectomized and control embryonic ovaries are similar at the tenth day. After this time Fugo observed that ovarian cortex of the hypophysectomized embryos failed to develop properly as compared with controls. If this work is correlated with the morphological studies, and if hormone is being produced, it might be concluded that the acidophil cells are responsible for the gonadotropic hormone. Fugo found that hypophysectomy had no effect on the development of the left ovarian medulla and right ovary. This is difficult to justify in view of the work of Domm and Dennis (32) and Venzke (153). The question might be solved by assuming that the basophils produce luteinizing hormone and that the acidophils produce follicle stimulating hormone. Since the time factor involved between 213 and 240 hours of incubation is so short, it does not seem plausible that the acidophil cells could produce their effect. Rahm (111) found indirect evidence that the hypophysis of the chicken exerts no influence on the gonads prior to puberty. This conclusion is not justified by the work of Fugo (40).

Smith and Dortsbach (134) and Nelson (97) detected gonadotropic and growth hormone early during the foetal life of the Sus scrofa. The gonadotropic hormones were found to precede the growth hormone. Their studies

indicated that the production of growth hormone coincides with the appearance of the basophil cells and that the gonadotropic hormone production coincides with the appearance of acidophil cells. These results do not entirely fit the situation in the chick embryo. Perhaps growth hormone is produced in the chick by the basophil cells, but growth, determined on the basis of mean body weight, does not take place rapidly until the acidophil cells appear in rather large numbers.

Although the chromaffin tissue in the embryonic adrenal glands at 228 hours has no regular arrangement, the cells are always in contact with a venous vessel. Thus it may be assumed that the chromaffin cells are active in the production of hormone. Sun (142) detected epinephrine in the adrenal glands at nine and one-half days of incubation. From a morphological point of view, the chromaffin tissue seems to function after 206 hours of development.

For the first time at 240 hours, acidophilic granules appear in some of the undifferentiated basophilic cells in the anterior lobe of the hypophysis. This observation has been previously made by Rahn (111). Two kinds of basophilic cells appear at this time, namely deeply and lightly staining cells. With the appearance of acidophilic granules in the cytoplasm of some of the cells of the anterior lobe, colloid droplets arise in some of the cells of the thyroid. The simultaneous appearance of acidophils in the hypophysis and colloid in the thyroid gland cells would suggest that the thyrotropic hormone is secreted by the acidophil

cells. Smith and Smith (133) found that the central part of the beef anterior pituitary, composed chiefly of basophil and chromophobe cells, is more effective in causing thyroid stimulation than the outer portion made up of acidophil and chromophobe cells. Allen (4) found that during metamorphosis of the tadpole the basophil cells are more numerous and stain more deeply than before metamorphosis. This work supports the view that the basophil cells secrete the thyroid-stimulating principle. D'Angelo (22) and (23), studying several species of Anura, observed that cytological activity of the basophil is related to hyperactivity of the thyroid, and may be concerned with the elaboration or release of a thyrotropic factor. However, Spaul and Howes (138) concluded that the thyrotropic (metamorphic) hormone is elaborated by the acidophils. The work of Rumph and Smith (125) supports the view that thyroid secretion is not necessarily initiated by pituitary stimulation.

Recent work of Martindale (88) points to the fact that the thyrotropic hormone is produced at least as early as the eleventh day of incubation.

Sun (142) found that the active principle of the thyroid is detectable at the tenth day. After this time there is an increase in both relative and absolute amount of active thyroid principle.

At 252 hours the most marked activity takes place in the testes where many primordial germ-cells are actively dividing. Whether this activity is the result of hypophysial function is open to question. Fugo (40) stated that the germ-cells are not affected, in the male, by the absence



of the pituitary. Cytologically the germ-cells in the hypophysectomized embryo do not differ from those of the controls.

Chromaffin cells of the adrenal glands at 252 hours are very granular, suggesting active secretion. Sun (142) found that the epinephrine content of the adrenal glands invariably increased in amount with the age of the embryo. Thus, it seems that the more granular the cell cytoplasm, the greater the hormonal content.

The number of thyroid cells containing chromophobe colloid globules or droplets is larger at 252 hours than at 240 hours, indicating that the gland is producing increased amounts of active thyroid principle. This morphological observation is verified by the chemical studies made by Sun (142). Acidophil cells continue to increase in number within the pars glandularis. This increase is associated with continued thyroid growth and the appearance of follicles at 260 hours. If the acidophil cells are assumed to be producing growth hormone, it is doubtful that there is much produced, since the difference in mean body weights of the ten and eleven day embryos is not great.

At 272 hours the acidophil cells appear in the posterior lobe of the pars glandularis. This cellular increase is associated with changes in the parathyroid glands, in which the cells are becoming acidophilic in nature. Perhaps this change marks the production of an active principle by the parathyroids. It also seems plausible to assume that the cortical cells of the adrenal are now secretory in function, since the cytoplasm

lightly with eosin and possesses a large, poorly chromatic nucleus. At the same time the thymus presents a well developed cortical and medullary zone. The thymus may now be assumed to be functional. According to Fugo (40), the thymus develops independently of the hypophysis. Perhaps the above observation is merely coincidence. It is interesting to note that the differentiation of the parathyroid glands keeps pace with the differentiation of the acidophilic elements of the pars glandularis.

Basophil and acidophil cells appear in the pars tuberalis at 331 hours, and the pars nervosa is well-developed at this period. The rather complete differentiation of the hypophysis at such an early period is responsible for producing growth of the entire endocrine system. The role which the active principles of the glands are playing with respect to each other, and to body growth in general, cannot be ascertained from a morphological study. However, from this time until hatching, the rate of body growth is greatly augmented, indicating a combined function of all the endocrine glands. It does not appear, from the work of Fugo (40), that the thyroid is directly concerned with body growth. By injecting thyrotropic substance into hypophysectomized embryos Fugo was able to restore the thyroid to normal appearance. This had no noticeable effect on body growth. It is apparent that the growth promoting factor of the pars glandularis is mainly responsible for body growth.

Marked cytological changes occur in the pars glandularis from 388 to 450 hours of development. From the work of Severinghaus (131) it may be

concluded that during this period the acidophils reach their peak of granular accumulation. If granulation is an index of secretory activity, it may be assumed that the pars glandularis is most active during this period. From 462 hours through hatching, the two lobes of the pars glandularis become cytologically distinct. On the basis of the work reported by Kleinholz and Rahn (71), it is plausible to assume that the light staining acidophil cells in the anterior lobe are responsible for the production of intermedin.

A marked cytological change occurs in the parathyroid glands at 400 hours. It is difficult to ascertain that the three types of cells described above are producing different active principles. It would seem more plausible to assume that they are cells in different stages of secretory activity. This statement is based on the fact that these cell types increase and decrease rather markedly in numbers throughout the remainder of the incubation period.

Little histological change takes place in the other endocrine glands from 400 hours until hatching. Growth, both of the body and of the glands, is the only striking change which occurs during this time interval.

Rahn (111) stated that in the chicken, the gonads do not elaborate sex hormone until puberty, as evidenced by the lack of comb growth. This observation is further substantiated by Demm and Dennis (32) and Venzke (153). These workers stimulated the intertubular tissue of the embryonic testes and the medulla of the left embryonic ovary, but the head furnishings showed no change over those of the controls. Therefore, it must be

assumed that the embryonic gonads do not produce sex hormone.

An attempt was made to determine whether the embryonic fluids of the chick embryo contained gonadotropic hormone during the incubation period from 168 to 384 hours. The fluids were pooled from a series of embryos at twenty-four hour intervals. Six cubic centimeters of embryonic fluid were injected over a period of four days into five twenty-one day female rats. The injected animals were killed on the fifth day, and the hypophysis, adrenals and ovaries weighed. The weights and histological structure of these glands did not differ significantly from those of the control rats. It is suggested that the embryonic fluids of the chick embryo do not contain gonadotropic hormone in sufficient quantity to produce ovarian stimulation in the rat.

## SUMMARY AND CONCLUSIONS

The morphogenesis of the hypophysis, thymus, thyroid, parathyroid, and adrenal glands, ovaries, and testes has been studied by means of serial, sagittal, transverse, and frontal sections, taken at approximately twelve hour intervals from the twelfth hour of incubation until hatching. The weights of these endocrine glands were taken from the tenth to the twenty-first day to determine whether sex differences occur in the rate of growth of the glands during the later one-half of the incubation period.

Hypophysis cerebri

1. The hypophysial pouch or Rathke's pocket first appears between 43 and 48 hours of incubation, and exhibits two lateral lobes from which the tuberal processes arise at 60 hours.
2. A definite hypophysial stalk is formed at 110 hours of incubation.
3. The infundibular process becomes very prominent at 134 hours.
4. The pars glandularis becomes a bilobed structure at about 134 hours of development. Its posterior lobe lies near the infundibular process, while the anterior lobe extends anteriorly and distally, giving rise to the tuberal processes which later develop into the pars tuberalis.
5. The pars nervosa develops from lateral out-pocketings of the

infundibular process and is prominent at 191 hours.

6. The hypophysial stalk begins to regress after 191 hours of incubation. At the same time Rathke's pocket disappears, leaving no evidence of a pars intermedia. The two halves of the pars tuberalis continue to grow toward the floor of the brain, and by hatching time, surround the infundibular stalk.

7. The anterior and posterior lobes of the pars glandularis are cytologically distinct in that the posterior lobe possesses acidophil, basophil and chromophobe cells, while the anterior lobe contains basophil, chromophobe, and weakly staining acidophil cells. The cellular elements of the pars glandularis are preceded by undifferentiated cells which take on basophilic tendencies at 191 hours of incubation. At 240 hours acidophilic cells make their appearance by differentiation from cells with basophil tendencies. The wave of acidophil cell differentiation begins in the anterior lobe and passes posteriorly to the posterior lobe as development progresses. After 240 hours the basophil cells become less plentiful. However, at this time light and dark staining basophil cell types can be distinguished in the pars glandularis. The dark staining basophilic cells give rise to the true basophil cells. From 388 through 450 hours of incubation the acidophil cells reach their peak of granular accumulation. This period of acidophil cell hyperactivity is followed by the appearance of the light staining acidophil cells in the anterior lobe at 462 hours. From 450 hours until hatching a definite zonation

of the basophil cells occurs.

8. A definite connective tissue sheath separates the pars glandularis from the pars nervosa.

9. Indirect evidence is presented to substantiate the hypothesis that gonadotropic hormone is secreted by the basophilic cells in the hypophysis at 213 hours of incubation.

10. The rate of growth, based on mean weight of the embryo, is most rapid after appearance of the acidophil cells in the hypophysis.

11. Indirect evidence is presented to substantiate the hypothesis that thyrotropic hormone is produced by the acidophil cells in the hypophysis at 240 hours.

12. The appearance of acidophil cells in the posterior lobe of the pars glandularis at 272 hours is associated with possible functioning of the parathyroid and adrenal cortical cells.

13. On the basis of the work reported by Kleinholz and Rahn (71), indirect evidence is reported to substantiate the hypothesis that the light staining acidophil cells produce intermedin.

14. There is no significant difference between the percentage weights of the male and female hypophyses from the tenth to the twenty-first day of incubation.

Glandula thyreoidae

15. The thyroid gland begins development from an unpaired median ventral invagination of the pharyngeal epithelium at about 36 hours of incubation.
16. The thyroid anlage loses connection with the pharynx at 96 hours and becomes bilobed by 120 hours of incubation.
17. Non-follicular spaces appear in the thyroid glands at 148 hours, and distinct epithelial cell plates appear at 165 hours of development.
18. Intracellular chromophobe colloid first appears at 240 hours, and the first primary follicles at 260 hours. Chromophilic colloid appears at 295 hours of incubation, at which time the follicles are typical of those present in the adult thyroid.
19. Primary follicular cavities are formed by secretion and coalescence of the chromophobic colloid which has its origin near the nucleus on the side of the cell next to the future lumen of the follicle. Growth of the follicles is achieved by fusion of the follicular epithelium with cells which have not yet organized into follicular formation, and by follicular cell division.
20. Since the follicular cells lining a follicle may secrete either chromophobic or chromophilic colloid, a follicle contains two types of colloid. Chromophobic colloid mixed with chromophilic colloid gives the follicular colloid a vacuolated appearance, and the previously described vacuoles in the follicular colloid are not true vacuoles.



21. The follicular epithelial cell height varies only slightly during embryonic life.

22. There is a progressive increase in the mean follicular diameters from 295 hours until hatching.

23. No sex differences occur between the percentage weights of the thyroid glands from the tenth to the twenty-first day.

24. Indirect evidence is presented to support an hypothesis that the thyroid glands are least active at nineteen days of incubation.

#### Glandula parathyreoides

25. The parathyroid primordium evaginates with that of the thyroid from the floor of the pharynx, migrates posteriorly, and becomes separated from the thyroid primordium as a lateral lobe at 148 hours. This is the anterior parathyroid lobe. After 165 hours of incubation the posterior lobe of the parathyroid gland becomes separated from the anterior lobe.

26. The parathyroid glands develop into cords of cells radiating from a central crescent-shaped epithelial cell cord.

27. Accessory parathyroid tissue is occasionally embedded in the posterior lobes of the thymus, under the capsule of the thyroid with thymic tissue, and in the ultimobranchial bodies.

28. Three types of cells, based on cellular structure and staining characteristics, are demonstrable in the parathyroid glands at 400 hours of incubation.

29. Indirect evidence is presented which indicates that the small lightly acidophilic staining cells in the parathyroid glands are responsible for the active principle initiating calcification of the embryonic skeleton.

#### Thymus

30. After 120 hours of incubation the double origin of the thymus can be observed. The large portion or thymus III is derived from the ventral and lateral wall of the third visceral pouch. Thymus IV, a smaller portion than thymus III, is derived from the dorsal wall of the intermediate part of the fourth visceral pouch and eventually fuses with thymus III.

31. An occasional large lymphocyte migrates into the periphery of the epithelial thymic tissue from the surrounding mesenchyme at 177 hours. Small thymic cells appear at 252 hours.

32. Connective tissue ingrowth from the primitive capsule, and growth and increase in the number of the epithelial cells produces the primary lobules at 213 hours of incubation.

33. Lymphocytes migrate into the thymic tissue along the interlobular septa.

34. Indirect evidence is presented to support the hypothesis that small lymphocytes (thymic cells) arise by cellular division from large lymphocytes.

35. A cortical and medullary zone can be distinguished in the thymus at 319 hours; but these zones are not definitely separated until 357 hours.

36. The medulla develops from the epithelial syncytium of the thymic primordium.
37. Hassall's corpuscles develop from the medullary epithelial cells.
38. Eosinophile cells do not appear in the thymus until late embryonic life. This also true of other cell types commonly found in this tissue.
39. No evidence was obtained to indicate that thymic development is dependent on the function of other endocrine glands.
40. The percentage weights of the developing thymi from the tenth to the twenty-first day are consistently less in the female as compared with the male.
41. The coefficient of variability is large for thymi of both sexes.

Glandula suprarenalis

42. The anlagen which give rise to the cortical substance of the adrenal gland appear between 90 and 96 hours as groups of cells derived from the coelomic epithelium.
43. Sympathetic cells derived from the primary sympathetic trunks have migrated between the cortical cells in the 134 hour embryo.
44. Masses of sympathetic cells appear along the dorso-medial surfaces of the adrenal glands at 148 hours. These sympathetic cell masses consist of two types of cells, namely ganglionic and non-ganglionic. It is believed that these cells arise from the secondary or definitive sympathetic trunks. Both of these cell types migrate into the adrenal tissue at 165 hours.

45. Indirect evidence indicates that the sympathetic cells, which arise from both the primary and secondary sympathetic trunks, transform into chromaffin tissue, since the migration of sympathetic cells into the adrenals takes place continuously throughout the incubation period. Because the penetration of sympathetic cells is more pronounced at certain periods, it is assumed that they migrate in waves.

The origin of chromaffin cells from the sympathetic cells is suggested by the scarcity of non-ganglionic and ganglionic cells in the adrenal glands at certain stages during development, indicating an almost complete transformation of the sympathetic cells into chromaffin cells. The intimate association of sympathetic and chromaffin cells is also indicative of sympathetic cell transformation.

Indirect evidence suggests that the ganglionic cells transform into chromaffin cells. This observation is based on these facts: they decrease in numbers; most of the chromaffin tissue is located near the periphery of the glands.

Indirect evidence also suggests that the chromaffin cells are derived from non-ganglionic rather than ganglionic cells, since chromaffin cells resemble non-ganglionic cells in structure, and because non-ganglionic cells are always numerous next to the cortical cords, where chromaffin cells differentiate.

The differentiation of sympathetic cells into chromaffin cells seems to be independent of the influence of cortical cords. This is indicated

by the fact that masses of sympathetic cells not in close proximity to the cortical cords differentiate into chromaffin cells.

46. The chromaffin cords arrange themselves with the gland so that some portion is next to a venous sinusoid.

The arterial system is confined almost entirely to the cortical tissue.

47. The mean adrenal weights and percentage gland weights from the tenth to the twenty-first day of incubation present no marked sex differences. There is a rather gradual decrease in the percentage weights in both sexes from the eleventh to the twenty-first day of incubation. The coefficient of variability is large.

#### Indifferent Gonads

48. From 90 to 96 hours a single layer of germinal epithelium covers the embryonic gonad. At this time the left gonad is larger than the right.

49. At 96 hours the left gonad contains approximately 70 per cent, while the right contains 50 per cent, of the total germ-cells counted in the gonads of four embryos.

50. The sexual cords of first proliferation become well developed between 134 and 165 hours of incubation.

51. At 165 hours the morphological sexual differences become apparent in the gonads.

Ovarium

52. The primordial germ-cells begin mitotic division at 191 hours, and reach a peak of proliferation between 213 and 228 hours.

53. Cortical cords, or the cords of second proliferation, are clearly demonstrable by 213 hours of incubation in the left ovary. The medullary portion of the left ovary is well-developed at this time.

54. The germinal epithelium covering the right ovary is reduced to a single layer of cuboidal cells at 228 hours with a result that the right ovary consists of medullary tissue. It is not until 284 hours that the germinal epithelium covering the left ovary is reduced to a single layer of cells.

55. From 307 hours until hatching the anterior and posterior poles of the left ovary are most active in the production of cortical cords.

56. Much variation in the size of the right ovary exists between embryos from 336 hours until hatching.

57. The mean weights of the left ovary increase from the tenth until the eighteenth day of incubation when they begin to plateau.

58. The percentage weights of the right ovary decrease from the tenth until the twenty-first day.

59. The percentage weights of the left ovary decreases slowly from the thirteenth day until hatching.

Testis

60. The seminiferous cords are discernible at 165 hours of incubation.
61. Seminiferous cords after 177 hours of incubation, comprise most of the male gonads because the germinal epithelium has been reduced to a single layer of cuboidal epithelium.
62. The primordial germ-cells are first observed in cellular division at 206 hours.
63. The intertubular tissue begins to increase at 213 hours and continues to increase until hatching.
64. Interstitial cells differentiate from the intertubular stroma and first appear at 272 hours.
65. From 307 hours until hatching discontinuous lumina appear in the seminiferous cords.
66. The mean testes weights increase progressively from the tenth to the twenty-first day of incubation.
67. Based on percentage weight the testes are lightest between the twelfth and fourteenth days and heaviest between the sixteenth and nineteenth days.

## LITERATURE CITED

1. Abel, W. Further observations on the development of the sympathetic nervous system in the chick. *Jour. Anat. and Physiol.* 47:35-72. 1912.
2. Achert, J. E., and Morris, M. H. Studies on the effect of thymectomy on growing chickens. *Anat. Rec.* 44:209. 1929. (Abstract of paper presented at the twenty-seventh annual meeting of the American Society of Zoologists, Des Moines, Iowa, Dec. 30-31, and Jan. 1, 1930).
3. Allen, B. M. The embryonic development of the rete-cords and sex-cords of *Chrysemys*. *Amer. Jour. Anat.* 5:79-94. 1905.
4. Allen, E. The dominant role of the pars anterior of the hypophysis in initiating amphibian metamorphosis. *Anat. Rec.* 54:65-81. 1932.
5. Aron, M. L'histogenèse de l'hypophyse chez les mammifères. *C. R., Ass. Anat.* 24:26-34. 1929.
6. Atwell, W. J. The relation of the chorda dorsalis to the entodermal component of the hypophysis. *Anat. Rec.* 10:19-41. 1915.
7. \_\_\_\_\_ The morphogenesis of the hypophysis cerebri of the domestic fowl during the second and third weeks of incubation. *Anat. Rec.* 73:57-71. 1939.
8. Atwell, W. J., and Sitler, I. The early appearance of the anlagen of the pars tuberalis in the hypophysis of the chick. *Anat. Rec.* 15:181-187. 1918.
9. Balfour, F. M. On the structure and development of the vertebrate ovary. *Quart. Jour. Micros. Sci.* 18:383-438. 1878.
10. Basch, K. Die Beziehung der Thymus zur Schilddrüse. *Zeit. f. exp. path. u. Therap.* (Berlin), 12:2-28. 1913.
11. Beard, J. The germ-cells, Part I. *Jour. Anat. and Physiol.* 38: 82-105. 1904.
12. Bencit, J. Sur la structure histologique d'un organe de nature testiculaire développée spontanément chez une poule ovario-tomisée. *C. R. Acad. Sci.* 177:1243-1246. 1923.



13. Benoit, J. Destruction des gonocytes primaires dans le blastoderme du poulet par les rayons ultraviolets, aux premiers stades du développement embryonnaire. Proc. 2nd. Internat. Congress. for Sex Res., London, 1930. pp. 162-170. Edinburgh, Oliver and Boyd, 1930.
14. Blocker, H. W. Embryonic history of the germ cells in *Passer domesticus* (L). Acta Zool. 14:111-161. 1933.
15. Bradway, W. Morphogenesis of the thyroid follicles of the chick. Anat. Rec. 42:157-167. 1929.
16. Breneman, W. R. Growth of the endocrine glands and viscera in the chick. Endocrinology. 28:946-954. 1941.
17. Brode, M. D. The significance of the asymmetry of the ovaries of the fowl. Jour. Morph. 46:1-57. 1928.
18. Bruni, A. C. Sullo sviluppo del lobo ghiandolare dell ipofisi negli amnioti. Internat. Monatschr. f. Anat. u. Physiol. 31:129-237. 1915.
19. Chen, G., Oldham, F. K., and Geiling, E. M. K. Appearance of the melanophore expanding hormone of pituitary gland in developing chick embryo. Proc. Soc. Exp. Biol. and Med. 45:810-813. 1940.
20. Collin, R. Recherches sur la glande pituitaire et la neurhypophyse des oiseaux. C. R. Ass. Anat. 21:166-170. 1926.
21. Cowdry, E. V. Special Cytology, Vol. 2. 2nd ed. New York. Paul B. Hoeber, Inc. 1932.
22. D'Angelo, S. A. The morphology of the pituitary and thyroid gland of several species of Anura during different phases of metamorphosis. Anat. Rec. 76:17. Supp. No. 2. 1940. (Abstract of paper presented at the fifty-sixth annual session of the American Association of Anatomists, Louisville, Ky., Mar. 20-22, 1940).
23. \_\_\_\_\_ An analysis of the morphology of the pituitary and thyroid glands in amphibian metamorphosis. Amer. Jour. Anat. 69:407-437. 1941.
24. Dantschakoff, W. Untersuchungen über die Entwicklung des Blutes und Bindegewebes bei den Vögeln. Anat. Hefte. 37:471-589. 1908.

25. Dantschakoff, W. Untersuchungen über die Entwicklung von Blut und Bindegewebe bei Vögeln. Das lockere Bindegewebe des Hühnchens im fetalen Leben. Arch. f. Mikros. Anat. 73:117-181. 1909.
26. \_\_\_\_\_ Keimzelle und Gonade. IA. Von der entodermalen Wanderzelle bis zur Urkeimzelle in der Gonade. Zeit. f. Wiss. Biol. 13:448-510. 1931.
27. Dantschakoff, W., Dantschakoff, W. Jr., and Bereskina, L. Keimzelle und Gonade. IA. Identität der Urkeimzellen und der entodermalen Wanderzellen. Experimentelle Beweise. Zeit. f. Biol. 14:323-375. 1931.
28. DeBeer, G. R. The comparative anatomy, histology and development of the pituitary body. London. Oliver and Boyd. 1926.
29. d'Hollander, F. Recherches sur l'oogenèse et sur la structure et la signification du noyau vitellin de Balbiani chez les oiseaux. Arch. d'Anat. Micros. 7:117-180. 1904.
30. DeLawder, M., Tarr, L., and Geiling, E. M. K. The distribution in the chicken's hypophysis of the so-called posterior lobe principle. Jour. Pharm. and Exp. Therap. 51:142-143. 1934.
31. Domm, L. F. Spermatogenesis following early ovariectomy in the Brown Leghorn fowl. Arch. f. Entwmech. d. Organ. 119:171-187. 1929.
32. Domm, L. F., and Dennis, E. A. Effect of pituitary hebin upon reproductive system of the chick embryo. Proc. Soc. Exp. Biol. and Med. 36:766-769. 1937.
33. Dursy, E. Zur Entwicklungsgeschichte des Kopfes des Menschen und der höheren Wirbelthiere. Tübingen. H. Laupp. 1869.  
(Original not seen; cited from Atwell 1915, p. 21).
34. Economo, C. J. Zur Entwicklung der Vogelhypophyse. Sitzungsber. Akad. Wiss. Vienna. Math. -nat. Kl., Abt. 3. 108:281-297. 1899.
35. Fell, H. B. Histological studies on the gonads of the fowl. I. Histological basis of sex-reversal. Brit. Jour. Exp. Biol. 1:97-130. 1923.
36. Firket, J. Recherches sur l'organogenèse des glandes sexuelles des oiseaux. Anat. Anz. 46:413-425. 1914.

37. Firket, J. Recherches sur l'organogenèse des glandes sexuelles chez les oiseaux. Arch. de Biol. 29:201-351. 1914.
38. \_\_\_\_\_ On the origin of germ cells in higher vertebrates. Anat. Rec. 18:309-316. 1920.
39. Forsyth, D. The comparative anatomy, gross and minute, of the thyroid and parathyroid glands in mammals and birds. Jour. Anat. and Physiol. 42:302-319. 1908.
40. Fugo, N. W. Effects of hypophysectomy in the chick embryo. Jour. Exp. Zool. 85:271-298. 1940.
41. Fusari, R. Contribuzione allo studio dello sviluppo delle capsule surrenali e del simpatico nel pollo e nei mammiferi. Arch. Sci. Med. 16:249-301. 1892.
42. \_\_\_\_\_ Contribution a l'étude du développement des capsules surrenales et du sympathique chez le poulet et les mammifères. Arch Ital. de Biol. 18:161-182. 1893.
43. Gatenby, J. B. The transition of peritoneal cells into germ cells in Gallus bankiva. Quart. Jour. Micros. Sci. 68:1-16. 1924.
44. Getzowa, S. Über die Glandula parathyreoides, intrathyreoidale Zellhaufen derselben und Reste des postbranchialen Körpers. Virchows Arch. 188:181-233. 1907.
45. Goormaghtigh, N. Organogenèse et histogenèse de capsule surrénale et du plexus coeliaque. Arch. de Biol. 31:83-172. 1921.
46. Goldsmith, J. B. The history of the germ cells in the domestic fowl. Jour. Morph. 46:275-315. 1928.
47. \_\_\_\_\_ The primordial germ cells of the chick. I. The effect on the gonad of complete and partial removal of the 'germinal crescent' and of removal of other parts of the blastodisc. Jour. Morph. 58:537-553. 1935.
48. Greenwood, A. W. Some observations on the thymus gland in the fowl. Proc. Roy. Soc. of Edinburgh. 50:26-37. 1929.
49. Greenwood, A. W., and Blyth, J. S. S. Thymus extirpation in the laying hen. Proc. Soc. Exp. Biol. and Med. 29:38-40. 1931.
50. Haller, B. Untersuchung über die Hypophyse und die Infundibularorgane. Gegenbaurs Morph. Jahrb. 25:31-114. 1898.

51. Hamilton, B. Zur Embryologie der Vogelthymus. II. Die Thymusentwicklung bei der Ente, neben einigen Beobachtungen über die Kiemenspaltorgane dieses Tieres. *Anat. Anz.* 44:417-439. 1913.
52. Harris, H. A. Observations on the origin of the adrenal glands in the chick. Masters' thesis, University of Chicago. 1928. (Original not seen; cited from Willier 1930, p. 204).
53. Hays, V. J. The development of the adrenal glands of birds. *Anat. Rec.* 8:451-474. 1914.
54. Herring, P. T. The histological appearances of the mammalian pituitary body. *Quart. Jour. Exp. Physiol.* 1:121-185. 1908.
55. Helgesson, C. Zur Embryologie der Vogelthymus. I. Die Thymusentwicklung beim Sperling (*Passer domesticus*). *Anat. Anz.* 43:150-172. 1913.
56. Heys, F. The problem of the origin of germ cells. *Quart. Rev. Biol.* 6:1-45. 1931.
57. Higgins, G. M., and Sheard, C. The effects of selective solar irradiation on the parathyroid glands of chicks. *Amer. Jour. Physiol.* 85:299-310. 1928.
58. Higgins, G. M., Foster, W. I., and Sheard, C. Further investigations on the effects of radiant energy on the development of the parathyroid glands of chicks. *Amer. Jour. Physiol.* 94:91-100. 1930.
59. His, W., Jr. Über die Entwicklung des Bauchsympathicus beim Hühnchen und Menschen. *Arch. f. Anat. u. Physiol. Suppl.* 137:170. 1897.
60. Hoffmann, C. K. Étude sur le développement de l'appareil uro-genital des oiseaux. *Verhandl. d. Konink. Akad. van Wetenschappen te Amsterdam. Deel.* 1:1-54. 1893.
61. Hogben, L. T., and Crew, F. A. E. Studies on internal secretion. II. Endocrine activity in foetal and embryonic life. *Brit. Jour. Exp. Biol.* 1:1-13. 1923.
62. Hopkins, M. L. Development of the thyroid gland in the chick embryo. *Jour. Morph.* 58:585-613. 1935.

63. Hutt, F. B., and Boyd, W. L. Idiopathic hyperparathyroidism and tetany in fowl. *Endocrinology*. 19:398-402. 1935.
64. Janosik, J. Bemerkungen über die Entwicklung der Nebenniere. *Arch. Mikros. Anat.* 22:738-746. 1885.
65.                      Histologisch-embryologische Untersuchungen über das Urogenital-system. *Sitzungsber. Akad. Wiss. Wien, Math.-nat. Kl.*, Abt. 3. 91:97-199. 1885.
66.                      Bemerkungen über die Entwicklung des Genitalsystems. *Sitzungsber. Akad. Wiss. Wien, Math.-nat. Kl.*, Abt. 3. 99:260-286. 1890.
67. Juhn, M., and Mitchell, J. B. On endocrine weights in Brown Leghorns. *Amer. Jour. Physiol.* 88:177-182. 1929.
68. Keibel, F., and Abraham, K. Normentafel zur Entwicklungsgeschichte des Hühnes (*Gallus domesticus*). *Normtaf. Entwgesch. Wirbeltiere*. 2:132. 1900.
69. Keith, M. M. A technique for fixing and removing chick blastodiscs and embryos from the egg shell. *Sci.* 74:268. 1931.
70. Kleinholz, L. H., and Rahn, H. The distribution of intermedin in the pars anterior of the chicken pituitary. *Proc. Nat. Acad. Sci.* 25:145-147. 1939.
71.                      The distribution of intermedin; a new biological method of assay and results of tests under normal and experimental conditions. *Anat. Rec.* 76:157-172. 1940.
72. Koneff, A. A. Adaptation of the Mallory-azan staining method to the anterior pituitary of the rat. *Stain Technology*. 13:49-52. 1938.
73. Krause, R. Mikroskopische Anatomie der Wirbeltiere in Einzeldarstellungen. Pt. 2 Berlin W. de Gruyber. 1921-23. (Original not seen; cited from Rahn 1939, p. 484).
74. Kuntz, A. The development of the sympathetic nervous system in birds. *Jour. Comp. Neur.* 20:283-308. 1910.
75. Landauer, W., and Aberle, S. Studies on the endocrine glands of the Prizale Fowl. *Amer. Jour. Anat.* 57:99-134. 1935.

76. Latimer, H. B. Postnatal growth of the body, systems, and organs of the Single-comb White Leghorn chicken. *Jour. Agri. Res.* 29: 363-397. 1924.
77. Laulanié, M. Sur le mode d'évolution et la valeur de l'épithélium germinatif dans le testicule embryonnaire du poulet. *C. R. Soc. Biol.* 3:87-89. 1886.
78. Leonard, S. L., and Richter, J. W. Endocrine weights of the bantam fowl. *Jour. Hered.* 27:363-366. 1936.
79. Lillie, F. R. The development of the chick. 2nd ed. New York. Henry Holt and Company. 1919.
80. Loisel, G. Les phénomènes de sécrétion dans les glandes génitales. *Revue générale et faits nouveaux. Jour. de l'Anat. et de la Physiol.* 40:536-562. 1904.
81. Lothringer, S. Untersuchungen an der Hypophyse einiger Säugethiere und des Menschen. *Arch. f. Mikros. Anat.* 28:257-292. 1886.
82. Lutz, B. R., and Case, M. A. The beginning of adrenal function in the embryo chick. *Amer. Jour. Physiol.* 73:670-678. 1925.
83. Lups, T. Über die Entwicklung der hypophysis cerebri bei der Ente und beim Hühnchen. *Anat. Anz.* 67:161-180. 1929.
84. Macowan, M. Observations on the ductless glands, the serum calcium, and egg-laying in the fowl. *Quart. Jour. Exp. Physiol.* 21: 383-392. 1932.
85. Mall, F. P. Entwicklung der Branchialbogen und Spalten des Hühnchens. *Arch. f. Anat. u. Physiol. Leipz.* 1:1-34. 1887.
86. Marine, D. Parathyroid hypertrophy and hyperplasia in fowls. *Proc. Soc. Biol. and Med.* 11:117-118. 1913-14.
87. \_\_\_\_\_ The thyroid, parathyroid and thymus. (In Cowdry, E. V. *Special Cytology*, Vol. 2, pp. 799-836. 2nd ed. New York. P. B. Hoeber, Inc. 1932).
88. Martindale, F. M. Initiation and early development of thyrotropic function in the incubating chick. *Anat. Rec.* 79:373-393. 1941.
89. Matsumoto, T. On the early localization and history of the so-called primordial germ cells in the chick embryo (preliminary report). *Sci. Reports Tôhoku Imp. Univ.*, 4 ser. (Biol.) 7:89-127. 1932.

90. Maughan, G. H. Some effects of thymus removal in chickens. *Amer. Jour. Physiol.* 123:319-325. 1938.
91. Maurer, S., and Lewis, D. The structure and differentiation of the specific cellular elements of the pars intermedia of the hypophysis of the domestic pig. *Jour. Exp. Med.* 36:141-156. 1922.
92. Miller, A. M. The development of the postcaval veins in birds. *Amer. Jour. Anat.* 2:283-298. 1903.
93. Minervini, R. Des capsules surrénales. Développement, structure, fonctions. *Jour. de l'Anat. et de la Physiol.* 40:449-492, 634-667. 1904.
94. Morgan, A. H., and Grierson, M. G. Effects of thymectomy in domestic fowl. *Anat. Rec.* 44:221. 1929. (Abstract of paper presented at the twenty-seventh annual meeting of the American Society of Zoologists, Des Moines, Iowa, Dec. 30-31, and Jan. 1, 1930).
95. \_\_\_\_\_ The effects of thymectomy on young fowls. *Anat. Rec.* 47:101-117. 1930.
96. Müller, W. Ueber Entwicklung und Bau der Hypophysis und des Processus infundibuli cerebri. *Jena. Zeit.* 6:354-425. 1871.
97. Nelson, W. O. Studies on the anterior hypophysis. I. The development of the hypophysis in the pig (*Sus scrofa*). II. The cytological differentiation in the anterior hypophysis of the foetal pig. *Amer. Jour. Anat.* 52:307-332. 1933.
98. Nonidez, J. F., and Goodale, H. D. Histological studies on the endocrines of chickens deprived of ultraviolet light. I. Parathyroids. *Amer. Jour. Anat.* 38:319-347. 1927.
99. Noodt, K. Zur normalen und pathologischen Histologie der Epithelkörperchen. *Virchows Arch.* 238:262-268. 1922.
100. Nussbaum, M. Zur Differenzirung des Geschlechts im Thierreich. *Arch. f. Mikros. Anat.* 18:1-121. 1880.
101. Pensa, A. Osservazioni a proposito di una particolarità di struttura del timo. *Boll. Soc. Med. Chir., Pavia.* 188. 1902. (Original not seen; cited from Cowdry 1932, p. 843).

102. Petersen, H. Anatomische Studien über die Glandulae parathyreoideae des Menschen. *Virchows Arch.* 17:413-434. 1903.
103. Pfeiffer, C. Notes sur le développement de l'hypophyse des oiseaux. *C. R. Soc. Biol.* 92:1091-1093. 1925.
104. Pokorny, F. Zur vergleichenden Anatomie der Hypophyse. *Zeit. f. d. Ges. Anat.* 78:308-331. 1926.
105. Poll, H. Die Entwicklung der Nebennierensysteme. (In Hertwig, O., ed. *Handbuch der vergleichenden und experimentellen Entwicklungslehre der Wirbeltiere*, Vol. 3, pt. 1, pp. 443-616. Jena. 9. Fischer 1906). (Original not seen; cited from Willier 1930, p. 218).
106. Popoff, N. L'ovule mâle et le tissu interstitiel du testicule chez les animaux et chez l'homme. *Arch. d. Biol.* 24:433-500. 1909.
107. Peris, E. G. Studies on the endocrines of reptiles. I. The morphology of the pituitary gland of the lizard (*Anolis carolinensis*) with special reference to certain cell types. *Anat. Rec.* 70 (Suppl. 3) 63. 1938. (Abstract of paper presented at the fifty-fourth annual session of the American Association of Anatomists, Pittsburgh, Pa. Apr. 14-16. 1938).
108. Prenant, A. Contribution a l'histogenèse du tube seminifère. *Internat. Monatschr. f. Anat. u. Physiol.* 6:1-30. 1889.
109. Rabl, H. Die Entwicklung und Structur der Nebennieren bei den Vögeln. *Arch. f. Mikros. Anat.* 38:492-523. 1891.
110. Rahn, H. The morphogenesis and cytological differentiation of the chick pituitary. *Anat. Rec.* 70 (Suppl. 3) 64. 1938. (Abstract of paper presented at the fifty-fourth annual session of the American Association of Anatomists, Pittsburgh, Pa. Apr. 14-16. 1938).
111. \_\_\_\_\_ The development of the chick pituitary with special reference to the cellular differentiation of the pars buccalis. *Jour. Morph.* 64:483-517. 1939.
112. Rahn, H., and Painter, B. T. A comparative histology of the bird pituitary. *Anat. Rec.* 79:297-311. 1941.
113. Rahn, H., and Drager, G. A. Quantitative assay of the melanophore-dispersing hormone during the development of the chicken pituitary. *Endocrinology.* 29:725-730. 1941.



114. Rathke, H. Über die Entstehung der Glandula pituitaria. Arch. f. Anat. Physiol. u. Wiss. Med. 4:482-485. 1838.
115. Rau, S. A., and Johnson, P. H. Observations on the development of the sympathetic nervous system and suprarenal bodies in the sparrow. Proc. Zool. Soc. London. 741-768. 1923.
116. Reagan, F. P. Early castration of the vertebrate embryo. Anat. Rec. 11:489-490. 1916.
117. Reichert, K. B. Das Entwicklungsleben im Wirbelthierreich. Berlin. A. Hirschwald. 1840. (Original not seen; cited from Atwell 1915, p. 21).
118. Remak, R. Untersuchungen über die Entwicklung des Wirbeltieres. Berlin. J. Reimer. 1851. (Original not seen; cited from Marine 1932, p. 800).
119. Richards, A., Hulpieu, H. R., and Goldsmith, J. B. A restudy of the germ cell history in the fowl. Anat. Rec. 34:158. 1926. (Abstract of paper presented at the twenty-fourth annual meeting of the American Society of Zoologists, Philadelphia, Pa. Dec. 27-29, 1926).
120. Riddle, O., and Schooley, J. P. Absence of follicle-stimulating hormone in pituitaries of young pigeons. Proc. Soc. Exp. Biol. and Med. 32:1610-1614. 1935.
121. Rossi, U. Sui lobi laterale della ipofisi. Monit. Zool. Ital. 7:240. 1896. (Original not seen; cited from Atwell 1939, p. 65).
122. Rubaschkin, W. Ueber das erste Auftreten und Migration der Keimzellen bei Vogelembryonen. Anat. Hefte. 35:241-261. 1907.
123. \_\_\_\_\_ Chondriosomen und Differenzierungsprozesse bei Säugetierembryonen. Anat. Hefte. 41:399-431. 1910.
124. Rudnick, D. Thyroid-forming potencies of the early chick blastoderm. Jour. Exp. Zool. 62:287-317. 1932.
125. Rumph, P., and Smith, P. E. The first occurrence of secretory products and of a specific structural differentiation in the thyroid and anterior pituitary during the development of the pig foetus. Anat. Rec. 33:289-298. 1926.

126. Sainmont, G. Recherches relatives à l'organogenèse du testicule et de l'ovaire chez le chat. *Arch. de Biol.* 22:71-162. 1906-07.
127. Sauer, F. G., and Latimer, H. B. Sex differences in the proportion of the cortex and the medulla in the chicken suprarenal. *Anat. Rec.* 50:289-298. 1931.
128. Schmiegelow, E. Studien über die Entwicklung des Hodens und Nebenhodens. *Arch. f. Anat. u. Physiol. Anat. Abt.* 157-168. 1882.
129. Schooley, J. P., and Riddle, O. The morphological basis of pituitary function in pigeons. *Amer. Jour. Anat.* 62:313-349. 1938.
130. Semon, R. Die indifferente Anlage der Keimdrüsen beim Hühnchen und ihre Differenzierung zum Hoden. *Jena. Zeit. Naturwiss.* 21:46-86. 1887.
131. Severinghaus, A. E. Cellular changes in the anterior hypophysis with special reference to its secretory activities. *Physiol. Rev.* 17:556-588. 1937.
132. Siler, K. A. The cytological changes in the hypophysis cerebri of the garter snake (*Thamnophis radix*) following thyroidectomy. *Jour. Morph.* 59:603-623. 1936.
133. Smith, P. E., and Smith, I. P. The topographical separation in bovine anterior hypophysis of the principle reacting with the endocrine system from that controlling general body growth, with suggestions as to the cell types elaborating these encretions. *Anat. Rec.* 25:150-151. 1923. (Abstract of paper presented at the thirty-ninth annual session of the American Association of Anatomists, University of Chicago, Chicago, Ill. Mar. 28-30, 1923).
134. Smith, P. E., and Dortzbach, C. The first appearance in the anterior pituitary of the developing pig foetus of detectable amounts of the hormones stimulating ovarian maturity and general body growth. *Anat. Rec.* 43:277-297. 1929.
135. Snyder, F. F. The presence of melanophore-expanding and uterus-stimulating substance in the pituitary body of early pig embryos. *Amer. Jour. Anat.* 41:399-409. 1928.
136. Soli, U. Contribution à la connaissance de la fonction du thymus chez le poulet et chez quelques mammifères. *Arch. Ital. Biol.* 52:353-370. 1909.

137. Soulié, A. H. Recherches sur le développement des capsules surrénales chez le vertébrés supérieurs. Jour. de l'Anat. et de la. Physiol. 39:197-293. 1903.
138. Spaul, E. A., and Howes, N. H. The distribution of biological activity in the anterior pituitary of the ox. Jour. Exp. Biol. 7: 154-164. 1930.
139. Stein, K. F. Early embryonic differentiation of the chick hypophysis as shown in chorio-allantoic grafts. Anat. Rec. 43:221-237. 1929.
140. Stendell, W. Die Hypophysis Cerebri. (In Oppel, A., Lehrbuch der vergleichenden Mikroskopischen Anatomie der Wirbeltiere, Vol. 8, pp. 1-168. Jena. Fischer 1914). (Original not seen; cited from Atwell 1915, p. 19).
141. Stieda, L. Untersuchungen über die Entwicklung der Glandula thymus, Glandula thyroidea und Glandula carotica. Leipz. Thesis. 38 pp. (Original not seen; cited from Cowdry, Special Cytology, Vol. 2, p. 838).
142. Sun, T. P. Histo-physiogenesis of the glands of internal secretion-thyroid, adrenal, parathyroid, and thymus-of the chicken embryo. Physiol. Zool. 5:384-396. 1932
143. Swift, C. H. Origin and early history of the primordial germ cells in the chick. Amer. Jour. Anat. 15:483-516. 1914.
144. \_\_\_\_\_ Origin of the definitive sex-cells in the female chick and their relation to the primordial germ cells. Amer. Jour. Anat. 18:441-470. 1915.
145. \_\_\_\_\_ Origin of the sex-cords and definitive spermatogonia in the male chick. Amer. Jour. Anat. 20:375-410. 1916.
146. Tarulli, L., and Lo Monaco, D. Ricerche sperimentali sul timo. Boll. Accad. Med. Roma. 23:311. 1897. (Original not seen; cited from Morgan and Grierson 1930, p. 102).
147. Terni, T. Il corpo ultimobranchiale degli uccelli (Ricerche embrilogiche, anatomiche e istologiche su Gallus Dom.). Arch. Ital. di Anat. e di Embriol. 24:407-531. 1927. (Original not seen; cited from Greenwood and Blyth 1931, p. 39).

148. Terni, T. Sul significato biologico del corpo ultimobranchiale. *Atti del Reale Ist. Ven. di Sci., let. ed arti.* 87:197-206. 1927-28.
149. Tilney, F. Contribution to the study of the hypophysis cerebri with special reference to its comparative histology. *Amer. Anat. Mem.* No. 2, 1-93. 1911. The Wistar Institute of Anatomy and Biology, Philadelphia.
150. \_\_\_\_\_ An analysis of the juxta-neural epithelial portion of the hypophysis cerebri, with an embryological and histological account of a hitherto undescribed part of the organ. *Internat. Monatschr. Anat. Physiol.* 30:258-292. 1913.
151. Tschaschin, S. Über die Chondriosomen der Urgeschlechtszellen bei Vogelembryonen. *Anat. Anz.* 37:597-607, 621-631. 1910.
152. Valenti, G. Delle capsule surrenali nel pello ed in alcuni mammiferi. *Pisa Soc. Tosc. Atti (Mem.).* 10:122-148. 1889.
153. Venzke, W. G. The response of the gonads of chick embryos to gonadogen. *Amer. Jour. Vet. Res.* 2:281-284. 1941.
154. Verdun, M. P. Sur les dérivés branchiaux du poulet. *C. R. Soc. Biol.* 5:243-244. 1898.
155. von Baer, K. E. Über die Entwicklungsgeschichte der Thiere. Pts. 1 and 2. Königsberg. Gebrüder Bornträger. 1828-1837.
156. von Berenberg-Gossler, H. Die Urgeschlechtszellen des Hühnerembryos am 3. und 4. Bebrütungstage, mit besonderer Berücksichtigung der Kern- und Plasmastrukturen. *Arch. f. Mikros. Anat.* 81:24-72. 1912.
157. von Mihalkowics, G. V. Untersuchungen über die Entwicklung des Harn- und Geschlechtsapparates der Amnioten. *Internat. Monatschr. f. Anat. u. Physiol.* 2:284-385, 387-433, 435-485. 1885.
158. Waldeyer, W. Eierstock und Ei. Ein Beitrag zur Anatomie und Entwicklungsgeschicht der Sexualorgane. *Leipz. Engelmann.* 1870. (Original not seen; cited from Swift 1915, p. 441).
159. Welsh, D. A. Concerning the parathyroid glands; A critical, anatomical, and experimental study. *Jour. Anat. and Physiol.* 32:293-307, 380-403. 1898.

160. Wiesel, J. Beiträge zur Anatomie und Entwicklung der menschlichen Nebenniere. *Anat. Hefte.* 19:481-522. 1902.
161. Willier, B. H. The effects of thyroid grafts on the development of the chick. *Anat. Rec.* 26:339-340. 1923. (Abstract of paper presented at the twenty-first annual meeting of the American Society of Zoologists, Cincinnati, Ohio, Dec. 27-29, 1923).
162. \_\_\_\_\_ The endocrine glands and the development of the chick. I. The effects of thyroid grafts. *Amer. Jour. Anat.* 33:67-103. 1924.
163. \_\_\_\_\_ The behavior of embryonic chick gonads when transplanted to embryonic chick hosts. *Proc. Soc. Exp. Biol. and Med.* 23:26-30. 1925.
164. \_\_\_\_\_ The development of implanted chick embryos following the removal of the 'primordial germ cells'. *Anat. Rec.* 34:158. 1926. (Abstract of paper presented at the twenty-fourth annual meeting of the American Society of Zoologists, Philadelphia, Pa. Dec. 27-29, 1926).
165. \_\_\_\_\_ Is embryonic sex differentiation in the chick modifiable by sex hormones of engrafted gonads? *Anat. Rec.* 37:163. 1927. (Abstract of paper presented at the twenty-fifth annual meeting of the American Society of Zoologists, Nashville, Tenn. Dec. 28-30, 1927).
166. \_\_\_\_\_ The specificity of sex, of organization, and of differentiation of embryonic chick gonads as shown by grafting experiments. *Jour. Exp. Zool.* 46:409-465. 1927.
167. \_\_\_\_\_ A study of the origin and differentiation of the suprarenal gland in the chick embryo by chorio-allantoic grafting. *Physiol. Zool.* 3:201-225. 1930.
168. \_\_\_\_\_ The embryological foundations of sex in vertebrates. In E. Allen, ed., *Sex and Internal Secretions*, Chap. IV. Baltimore. Williams and Wilkins, Co. 1932.
169. \_\_\_\_\_ Experimentally produced sterile gonads and the problem of the origin of germ cells in the chick embryo. *Anat. Rec.* 70:89-112. 1937.
170. Witschi, E. Origin of asymmetry in the reproductive system of birds. *Amer. Jour. Anat.* 56:119-141. 1935.

171. Woerdeman, M. W. Vergleichende Ontogenie der Hypophysis. Arch. Mikros. Anat. 86:198-291. 1914.
172. Woodger, J. H. Observations on the origin of the germ cells of the fowl (*Gallus domesticus*) studied by means of their Golgi bodies. Quart. Jour. Micros. Sci. 69:445-462. 1925.
173. Woodside, G. L. Experimentally induced hyperthyroidism in the chick embryo. Anat. Rec. 67:423-430. 1937.
174. Yoshikawa, T. Supplementary study of the morphogenesis of the thyroid gland in the chick. Jour. Coll. Agri. Imp. Univ. Tokyo. 11:57-74. 1930.

## ACKNOWLEDGMENTS

The writer wishes to extend his sincere thanks and appreciation to Dr. H. L. Foust for the inspiration, guidance, and constructive criticism so graciously given throughout the investigation. Sincere thanks are extended to Dr. M. Lois Calhoun for the preparation of the photomicrographs. The writer wishes to thank the staff of the Department of Poultry Husbandry for their excellent cooperation in obtaining the fertile eggs used in this investigation.

Plate I

Explanation of figures

Figures 1 to 3. Parasagittal sections of the chick hypophysis which approach the mid-sagittal line. Hematoxylin-eosin. 200 X.

Fig. 1. Rathke's pouch or the hypophysial pouch at 48 hours of development. Observe the wide opening into the oral cavity.

- a. Oral cavity.
- b. Rathke's pouch or hypophysial pouch.
- c. Prosencephalon.

Fig. 2. The lateral lobes are protruding laterally and anteriorly. The section was taken from a 96-hour chick embryo.

- a. Lateral lobe.
- b. Hypophysial pouch.

Fig. 3. A section taken from a 148-hour embryo.

- a. Oral cavity.
- b. Hypophysial stalk.
- c. Bending point of the pars glandularis.
- d. Pars tuberalis.
- e. Tuberal process.
- f. Portions of the residual lumen.
- g. Infundibular process.
- h. Infundibulum.



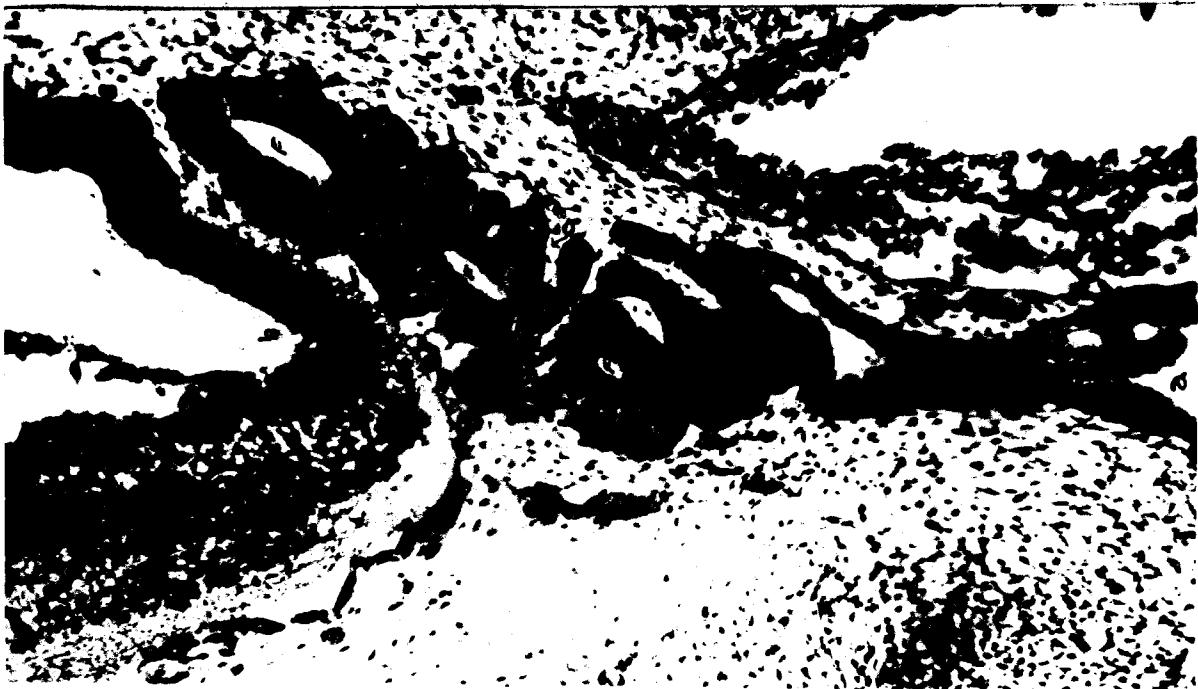
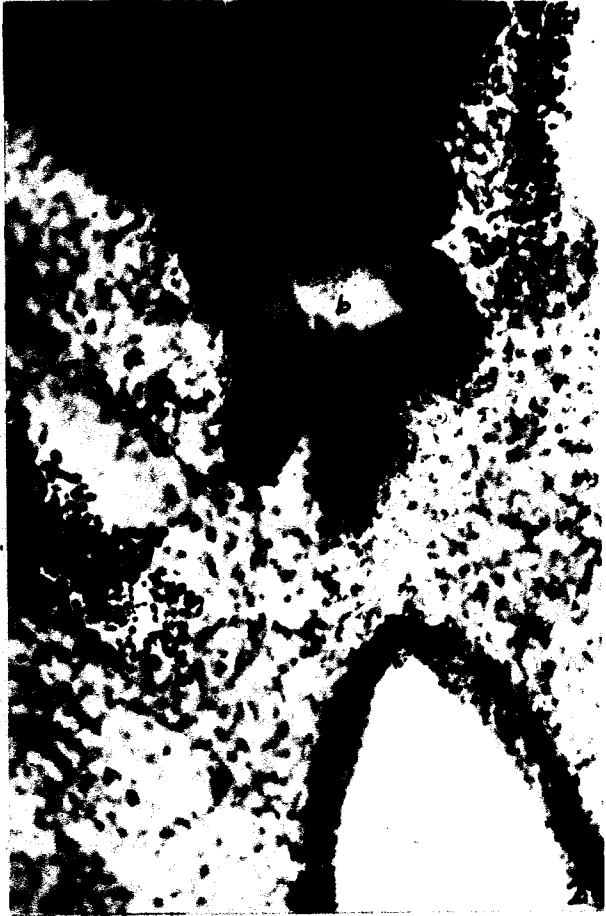
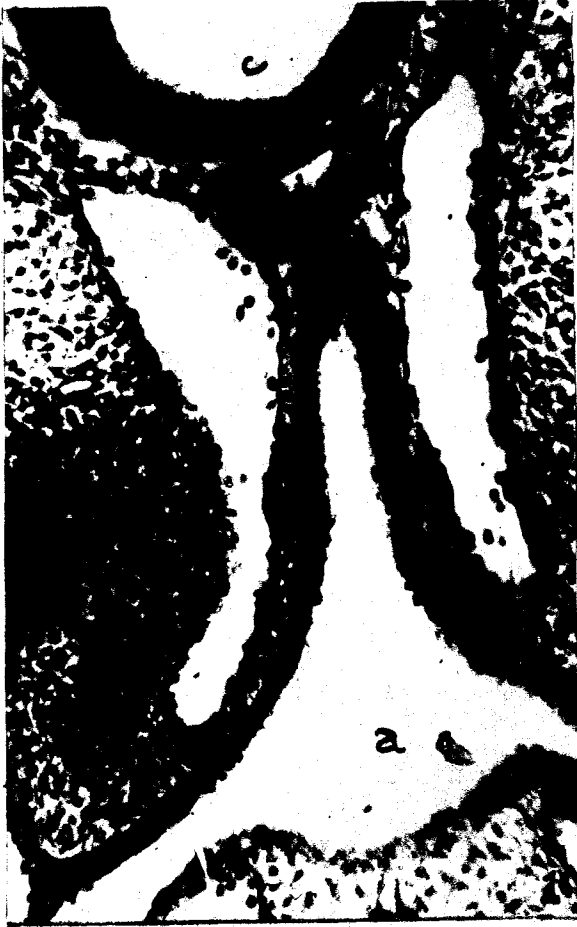Plate II

Explanation of figures

Fig. 4. Pars glandularis at 228 hours of development. Observe the grooves on either side occupied by the internal carotid arteries. The grooves partially divide the pars glandularis into a larger anterior, and a smaller posterior lobe. Mallory-azan (modified). 100 X.

- a. Anterior lobe.
- b. Posterior lobe.
- c. Carotid arteries.

Fig. 5. Hypophysis from a 272-hour chick embryo. Mallory-azan (modified). 100 X.

- a. Acinus.
- b. Residual lumen.
- c. Lateral diverticula of the infundibular process.

Fig. 6. Pars glandularis from a 375-hour chick embryo. Observe the dark basophilic cell cords near the infundibulum. Mallory-azan (modified). 200 X.

- a. Infundibulum.
- b. Residual lumen.

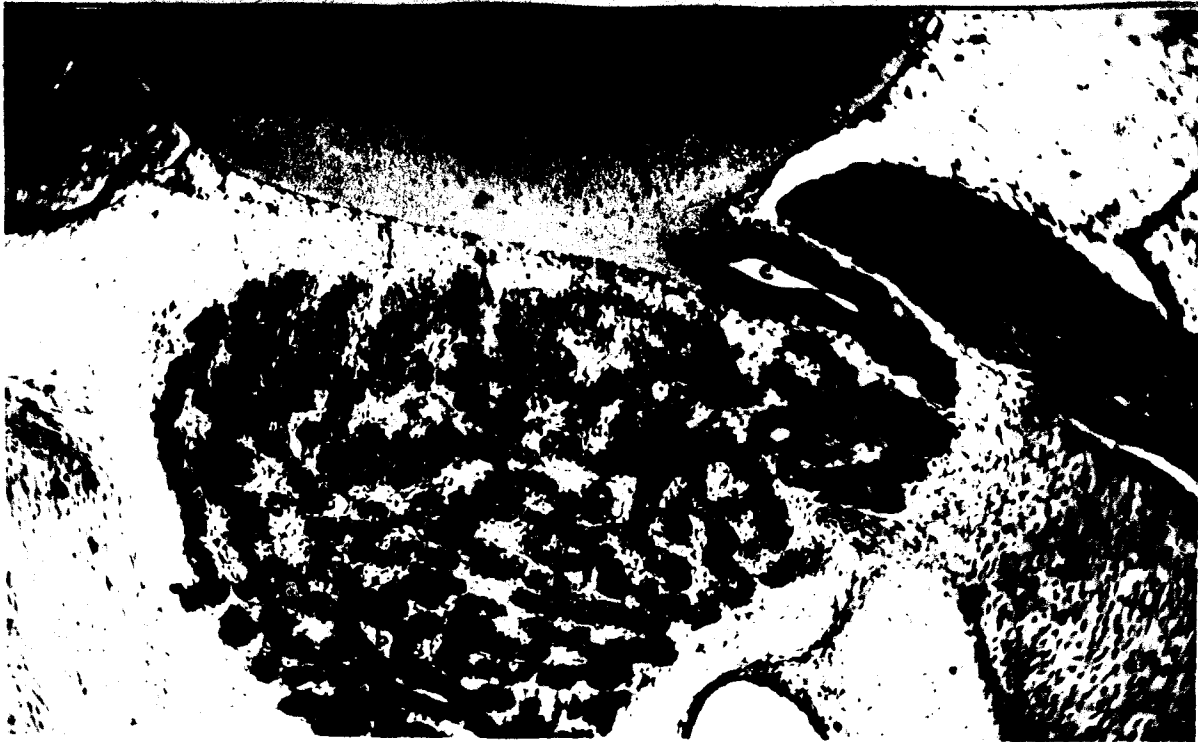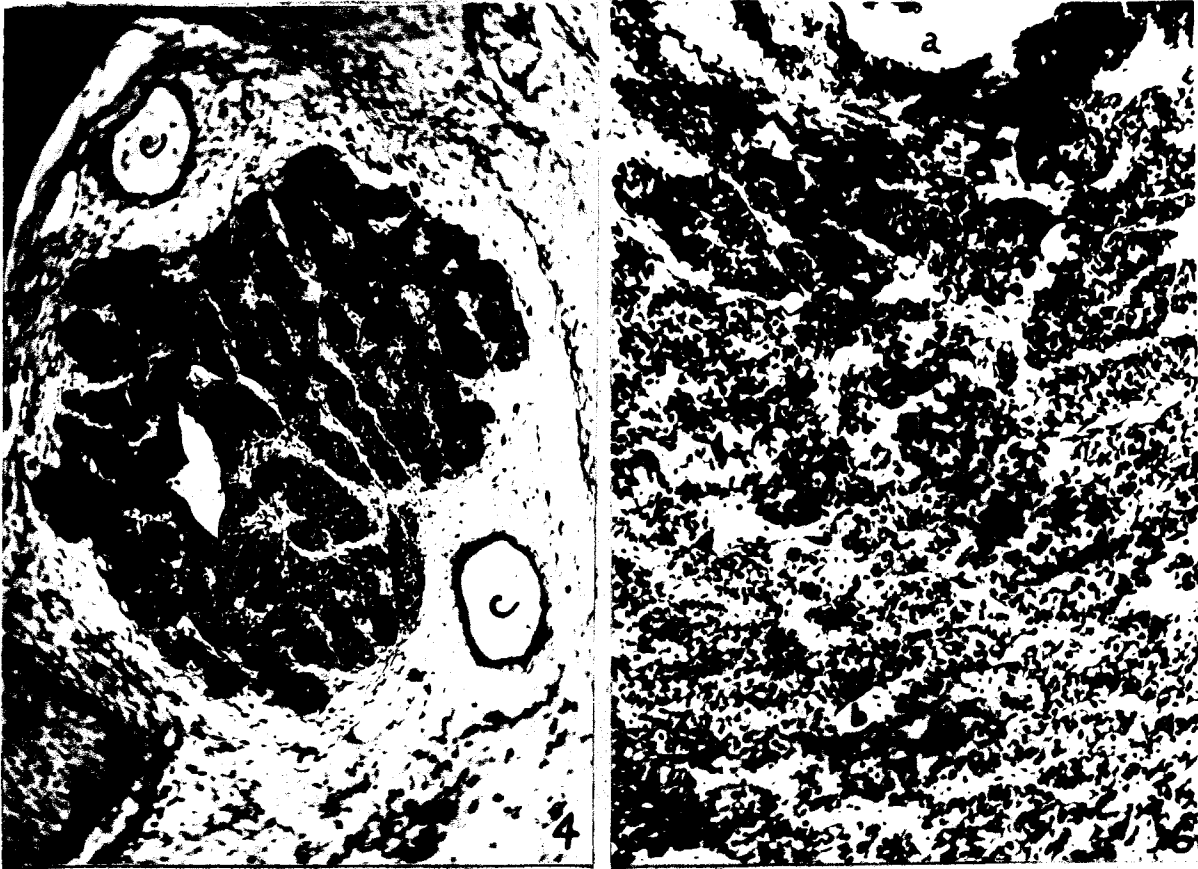


Plate III

Explanation of figures

Fig. 7. A sagittal section from the hypophysis of a 412-hour chick embryo. Observe the relations of the pars glandularis, the infundibulum, and the pars nervosa represented by three lateral out-pocketings of the infundibular process. Hematoxylin-eosin. 100 X.

- a. Acinus.
- b. Connective tissue.
- c. Portion of pars tuberalis.
- d. Infundibulum.
- e. Lateral outpocketings of infundibular process.

Fig. 8. A sagittal section from the hypophysis of a 462-hour chick embryo. The dark staining acidophils are predominate in the posterior lobe. The anterior lobe contains very weak-staining acidophil cells. Mallory-azan (modified). 100 X.

- a. Anterior lobe.
- b. Posterior lobe.
- c. Internal carotid artery.
- d. Connective tissue.
- e. Layer of cells from the pars tuberalis.
- f. Pars nervosa.

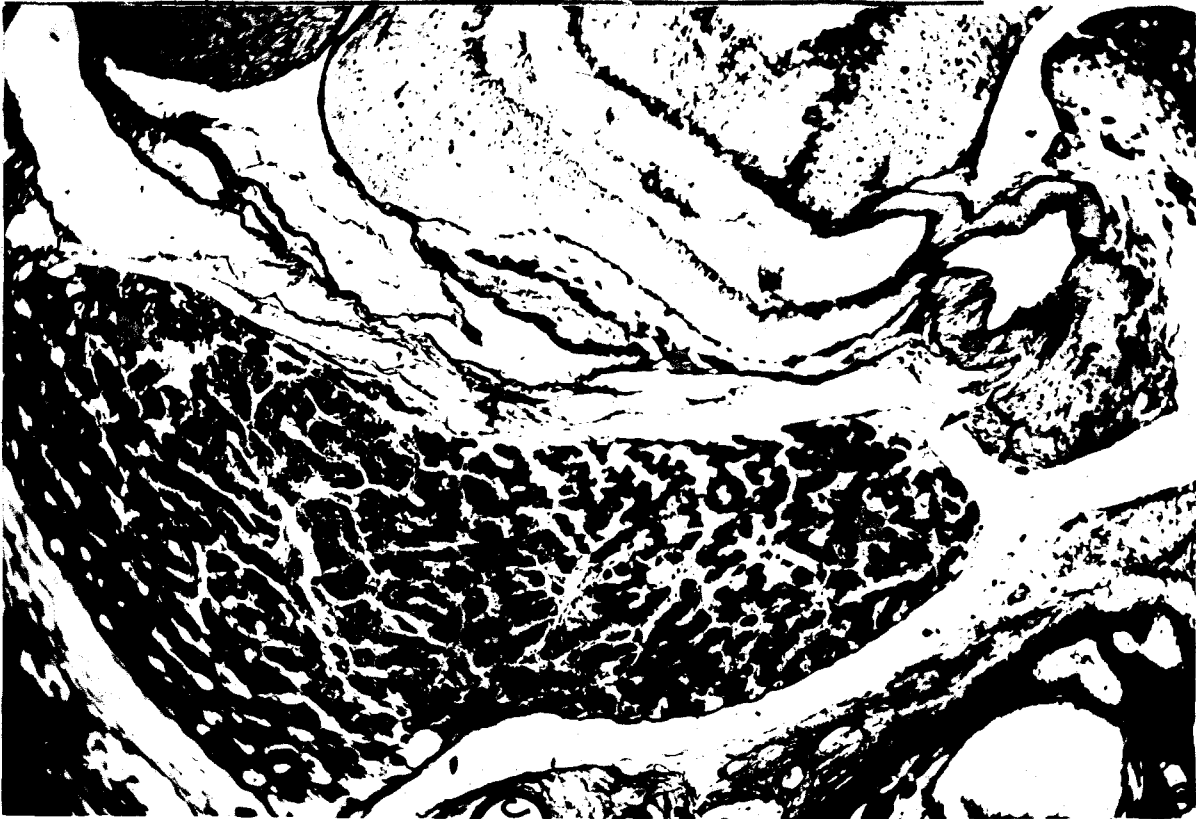
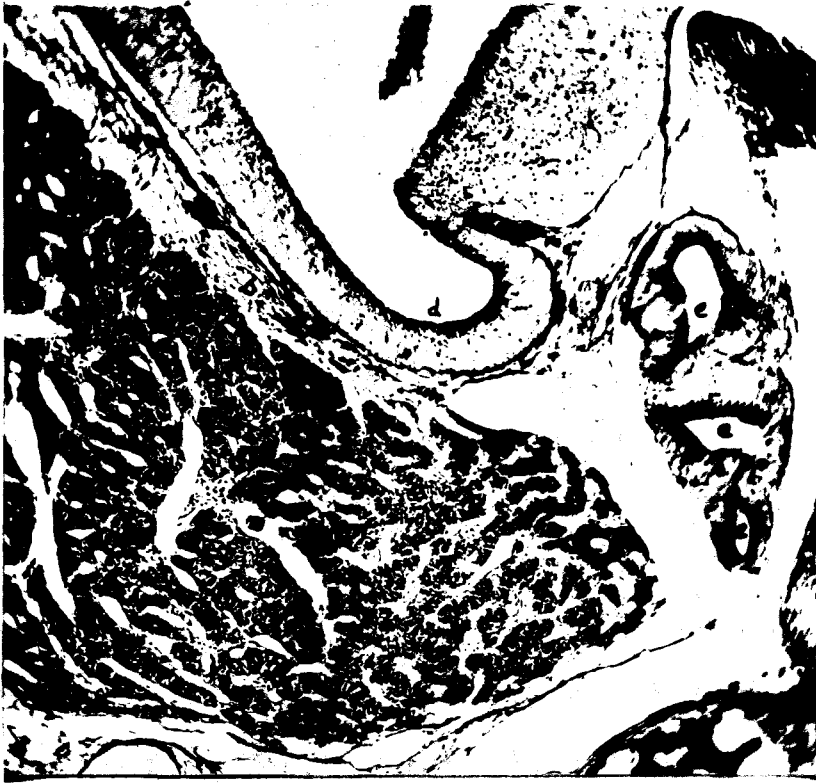

Plate IV

Explanation of figures

Fig. 9. A sagittal section taken from a 72-hour chick embryo. Observe the high columnar cells and the saucer-shaped depression in the epithelium of the floor of the pharynx. This is a beginning stage of thyroid-gland development. Hematoxylin-eosin. 200 X.

Fig. 10. A transverse section taken from a 110-hour chick embryo. The thyroid primordium has lost connection with the pharyngeal epithelium and is a spherical mass of cells migrating posteriorly to its intrathoracic position. Hematoxylin-eosin. 200 X.

Fig. 11. A sagittal section taken from a 120-hour chick embryo. The thyroid primordium has just become bilobed. Hematoxylin-eosin. 200 X.

a. Thyroid lobes.

Fig. 12. A sagittal section taken from a 148-hour chick embryo. On the postero-lateral surface of the thyroid lobe a group of cells are being detached and will become the anterior lobe of the parathyroid gland. The parathyroid primordium becomes detached from the thyroid lobe as a result of mesenchymal connective tissue invasion into the thyroid tissue. Hematoxylin-eosin. 200 X.

- a. Thyroid lobe.
- b. Parathyroid primordium.
- c. Oesophagus.
- d. Trachea.
- e. Thymic primordium.

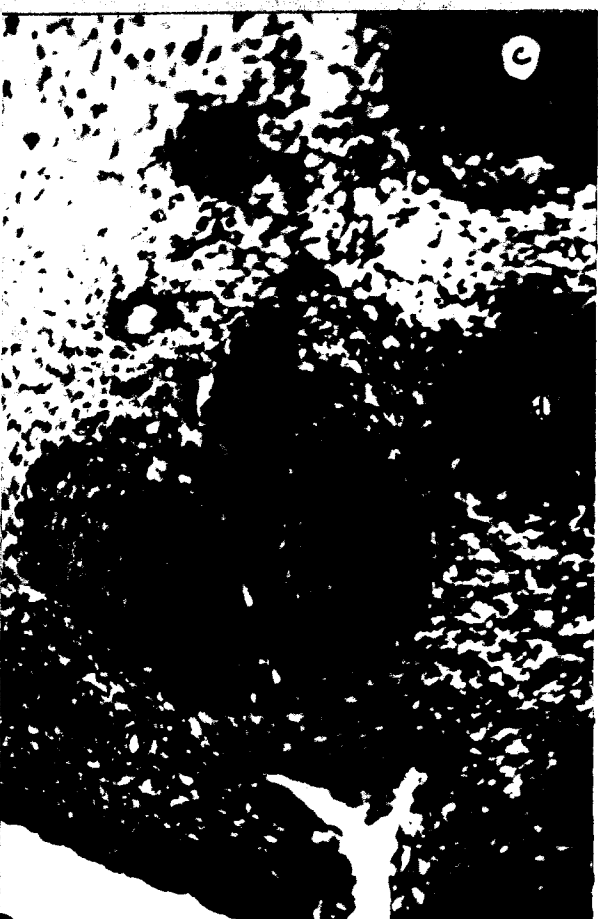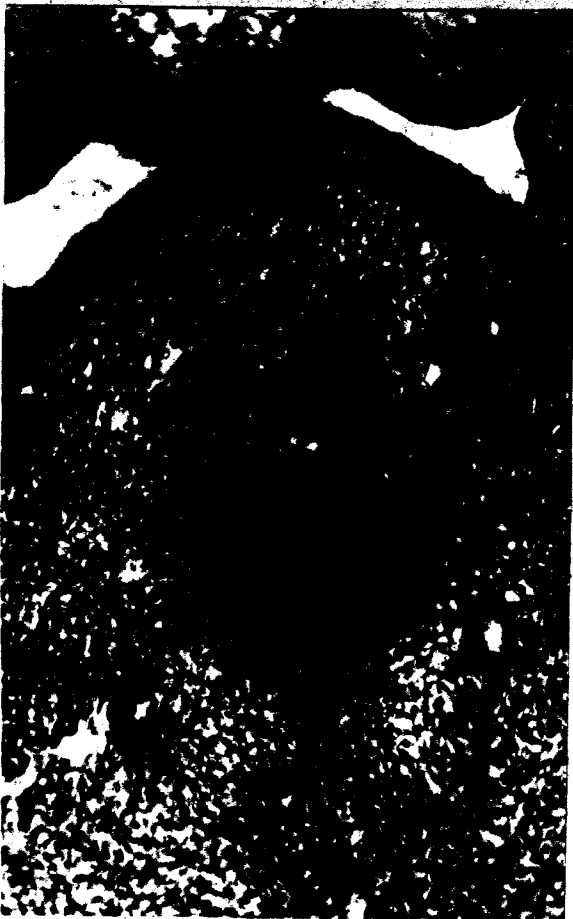


Plate V

Explanation of figures

Fig. 13. A sagittal section taken from a 165-hour chick embryo. At this time the parathyroid primordium has migrated posteriorly from the thyroid lobe and is detaching a group of cells which become the small posterior lobe of the parathyroid gland. Hematoxylin-eosin. 100 X.

- a. Thyroid lobe.
- b. Parathyroid primordium which will become the anterior lobe.
- c. Parathyroid primordium which will become the posterior lobe.

Fig. 14. A sagittal section taken from a 213-hour chick embryo. Observe the cord-like arrangement of the thyroid tissue and the non-follicular spaces between the epithelial cords. The small posterior lobe of the parathyroid gland has migrated posteriorly since its detachment from the anterior lobe parathyroid primordium. Hematoxylin-eosin. 200 X.

- a. Thyroid lobe.
- b. Anterior lobe of parathyroid gland.
- c. Posterior lobe of parathyroid gland.

Fig. 15. A section of thyroid tissue taken from a 240-hour chick embryo. Careful examination will reveal clear cytoplasm about some of the epithelial cell nuclei. These clear cytoplasmic areas contain chromophobic colloid. Hematoxylin-eosin. 400 X.

Fig. 16. A section of thyroid tissue taken from a 272-hour chick embryo. Observe the clear cytoplasmic areas about some of the nuclei. Hematoxylin-eosin. 400 X.

- a. Follicles containing chromophobic colloid.






Plate VI

Explanation of figures

Fig. 17A sagittal section taken from a 272-hour chick embryo. Observe the relations of the thyroid and parathyroid lobes. The convoluted cord-like growth of the parathyroid lobes is distinct. Hematoxylin-eosin. 100 X.

- a. Thyroid lobe.
- b. Anterior lobe of parathyroid.
- c. Posterior lobe of parathyroid.

Fig. 18. A section of thyroid tissue taken from a 295-hour chick embryo. Hematoxylin-eosin. 400 X.

- a. Primary follicles.
- b. Vascular spaces.

Fig. 19. A section of thyroid tissue taken from a 375-hour chick embryo. Hematoxylin-eosin. 400 X.

- a. Primary follicles containing chromophilic and chromophobic colloid.

Fig. 20. A section of parathyroid tissue taken from a 388-hour chick embryo. Hematoxylin-eosin. 400 X.

- a. Connective tissue capsule.

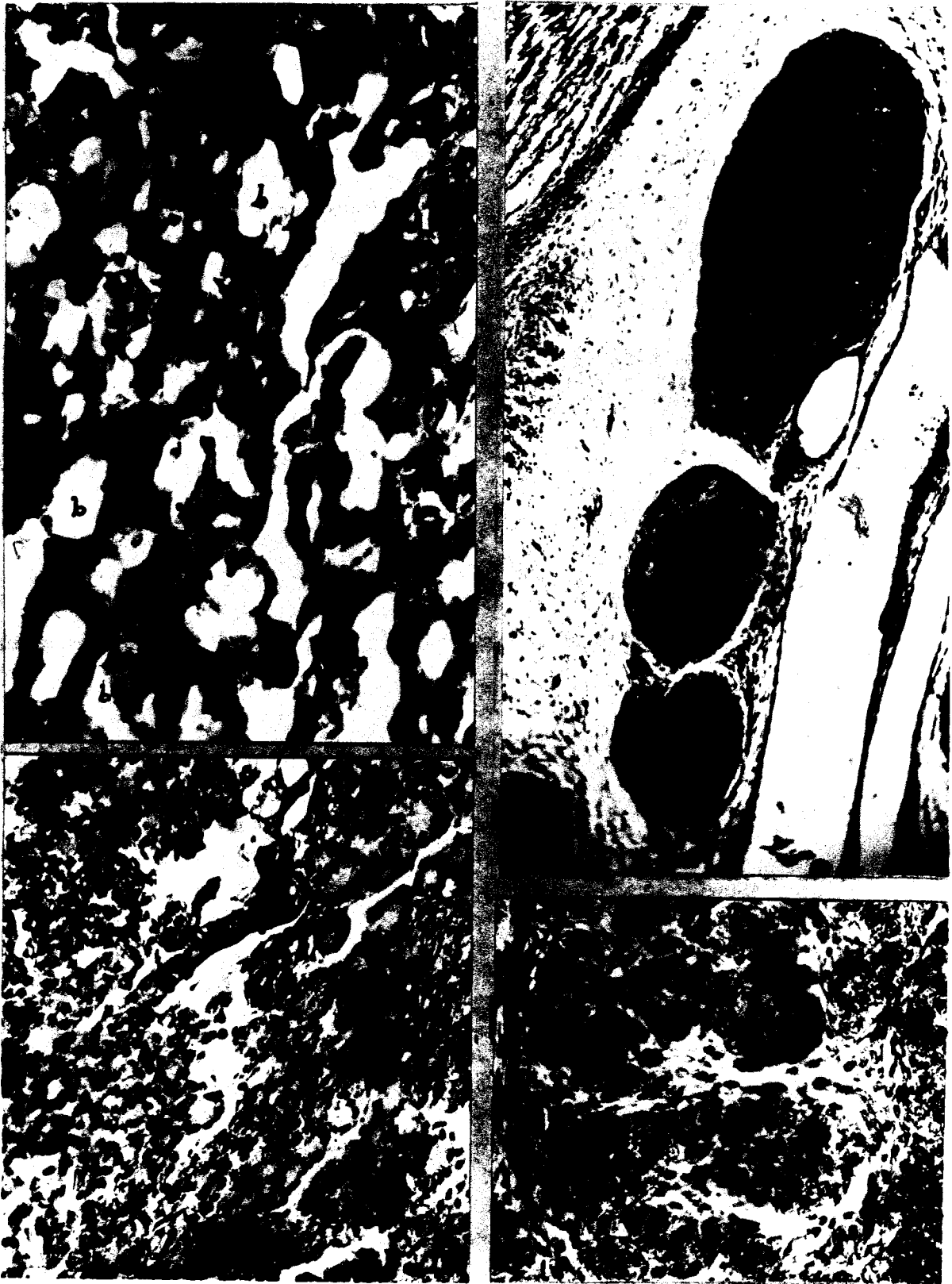


Plate VII

Explanation of figures

Fig. 21. A section of thyroid tissue taken from a 400-hour chick embryo. Several of the follicles appear to have tube-like openings into the surrounding vascular space. These openings, however, are not true openings, but rather follicular epithelial cells filled with chromophilic colloid. Note the simple squamous epithelium lining the vascular spaces and its relation to the follicle. Hematoxylin-eosin. 400 X.

- a. Arrow points to tube-like opening.
- b. Vascular space.
- c. Follicle containing chromophobic colloid.
- d. Follicle containing chromophilic colloid.
- e. Follicle containing both chromophobe and chromophilic colloid.

Fig. 22. A section from the thyroid gland of a 458-hour chick embryo. Hematoxylin-eosin. 400 X.

- a. Follicle containing both chromophobic and chromophilic colloid.

Fig. 23. A section of parathyroid tissue taken from a 450-hour chick embryo. Hematoxylin-eosin. 400 X.

Fig. 24. A section of parathyroid tissue taken from a 474-hour chick embryo. Hematoxylin-eosin. 200 X.

- a. Anterior lobe.
- b. Posterior lobe.
- c. Connective tissue separating the two lobes.

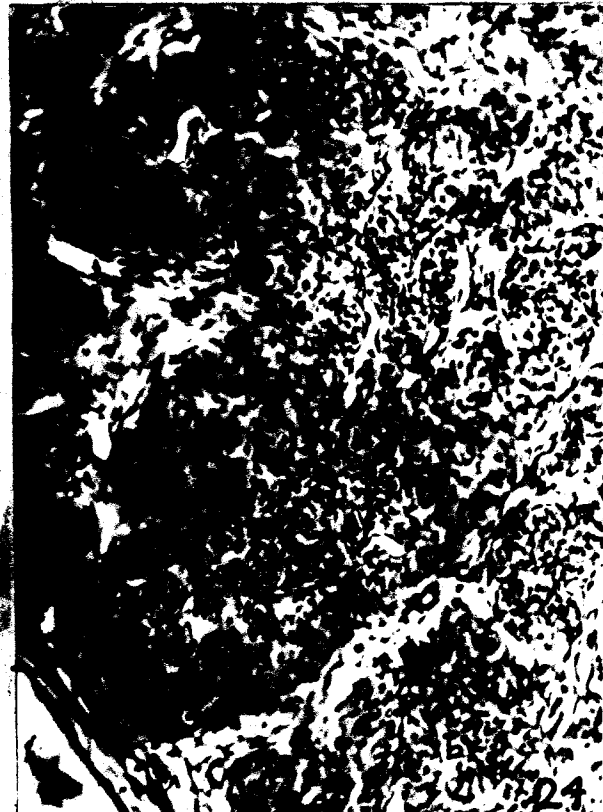
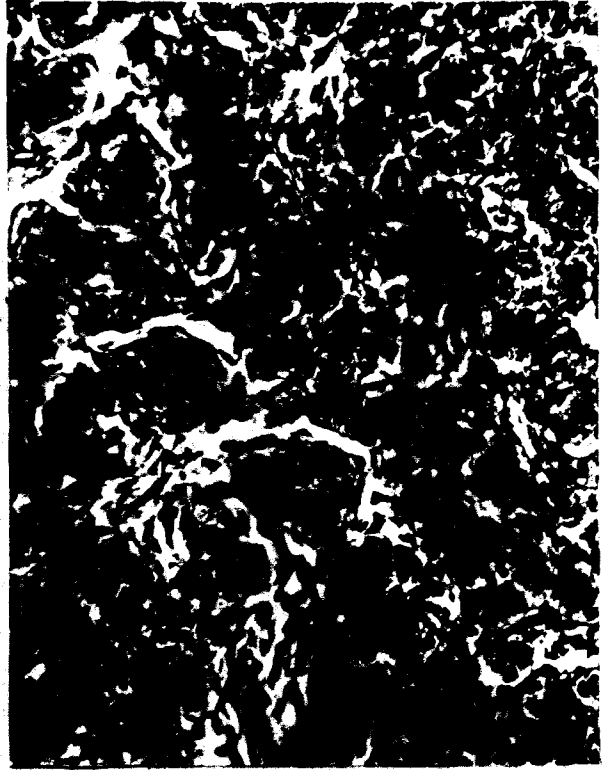


Plate VIII

Explanation of figures

Fig. 25. A section of thyroid tissue taken from a 474-hour chick embryo. Hematoxylin-eosin. 100 X.

Fig. 26. The section of tissue is taken from a 120-hour chick embryo, and presents the double origin of the thymus from visceral pouch III and IV. The small evagination from the posterior and ventral floor of visceral pouch IV becomes the ultimobranchial body. Hematoxylin-eosin. 100 X.

- a. Pharynx.
- b. Visceral pouch III.
- c. Visceral pouch IV.
- d. Evagination which becomes the ultimobranchial body.

Fig. 27. A section of tissue taken from the cephalic region of the neck in a 165-hour chick embryo. Observe the large number of lymphocytes outside the large blood vessel in the surrounding mesenchyme. These lymphocytes at a later period migrate into the thymic primordia. Hematoxylin-eosin. 200 X.

- a. Blood vessel.
- b. Lymphocytes.

Fig. 28. A section of thymic tissue taken from a 284-hour chick embryo before a definite cortex, and medulla has formed. Hematoxylin-eosin. 200 X.

Fig. 29. A section of thymic tissue taken from a 319-hour chick embryo after lobule formation has occurred. Hematoxylin-eosin. 200 X.

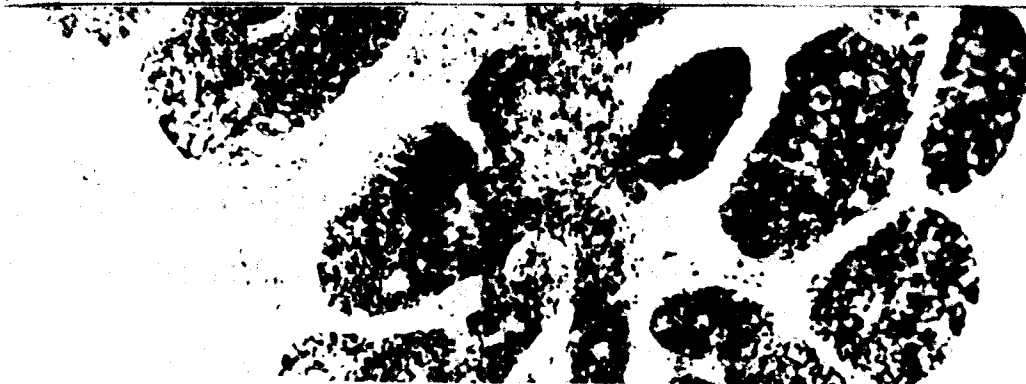
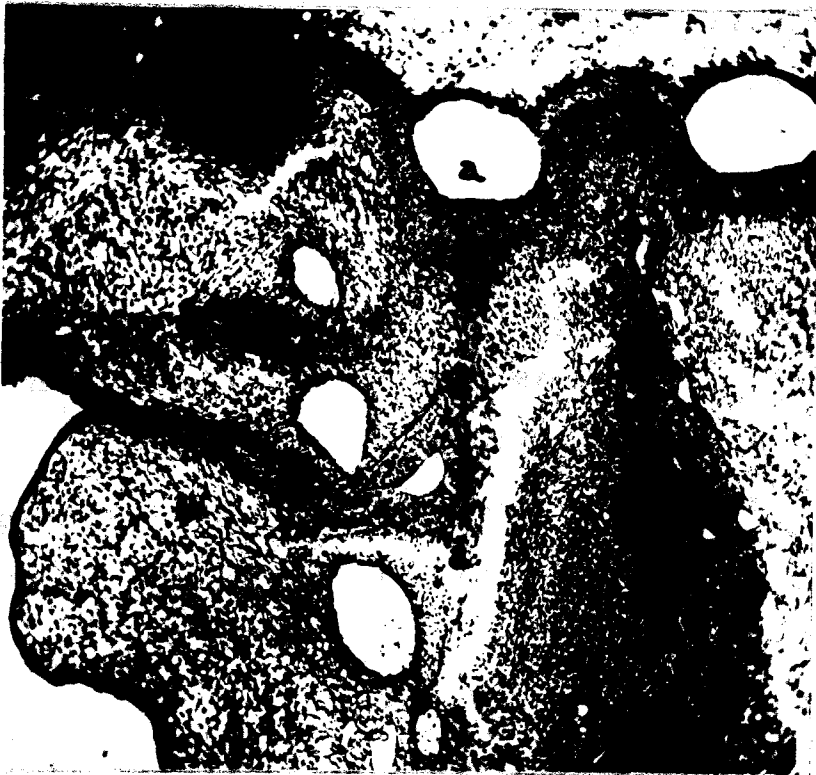



Plate IX

Explanation of figures

Fig. 30. A section of thymic tissue taken from a 375-hour chick embryo. Hematoxylin-eosin. 200 X.

- a. Medulla of thymic lobule.
- b. Cortex of thymic lobule.

Fig. 31. A section of thymic tissue taken from a 400-hour chick embryo. Hematoxylin-eosin. 200 X.

- a. Medulla of thymic lobule.
- b. Cortex of thymic lobule.
- c. Beginning formation of Hassall's corpuscle.

Fig. 32. A section of thymic tissue taken from a 474-hour chick embryo. Hematoxylin-eosin. 200 X.



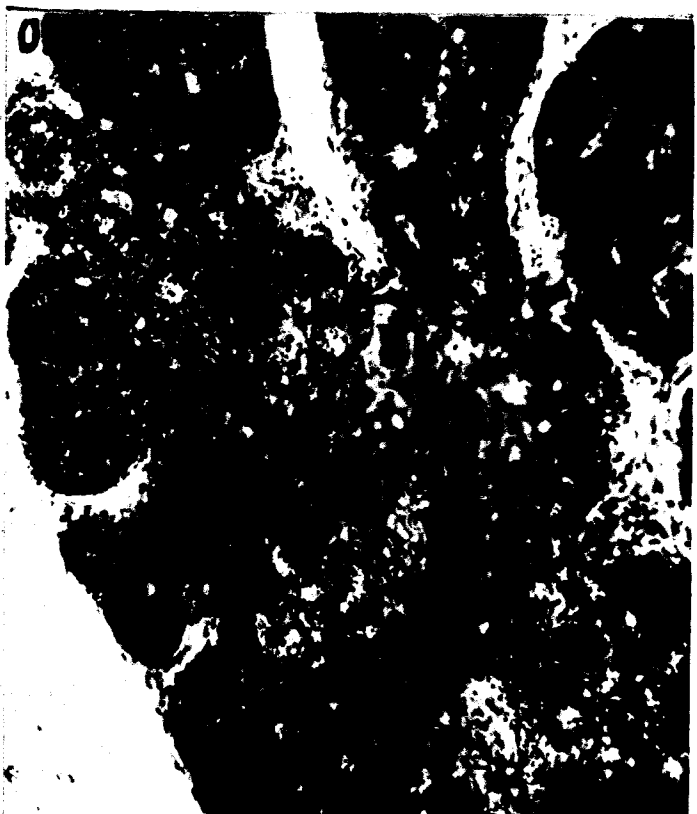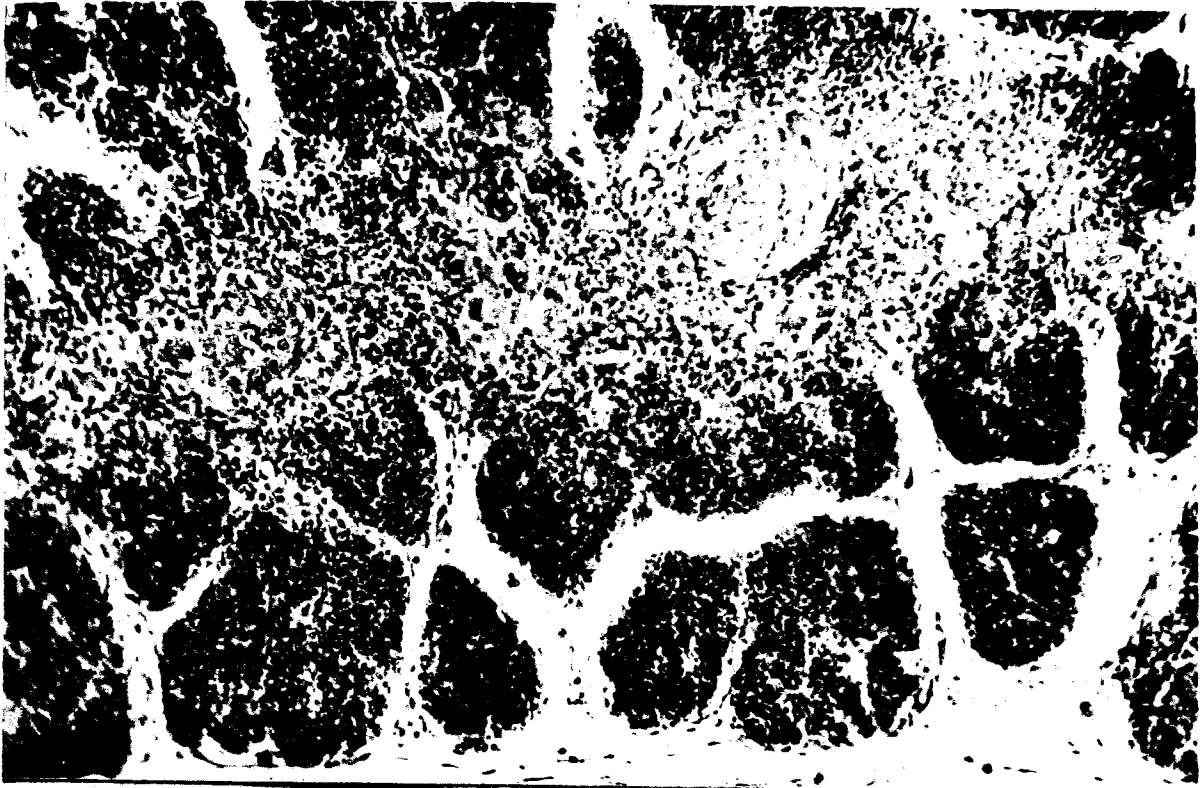


Plate X

Explanation of figures

Fig. 33. A transverse section taken through the abdominal cavity of a 120-hour chick embryo showing a portion of the adrenal cortical primordium. Hematoxylin-eosin. 200 X.

a. Adrenal cortical primordium.

Fig. 34. A sagittal section taken from a 165-hour chick embryo presenting the relations of the gonad, mesonephros, and adrenal gland. Hematoxylin-eosin. 100 X.

a. Adrenal gland.  
b. Gonad.  
c. Mesonephros.

Fig. 35. A sagittal section taken from a 228-hour chick embryo presenting the cord-like arrangement of the adrenal tissue and its relation to the testis. Hematoxylin-eosin. 100 X.

a. Adrenal gland.  
b. Testis.

Fig. 36. A sagittal section of adrenal tissue taken from a 272-hour chick embryo. Iron hematoxylin. 400 X.

a. Venous sinusoid.  
b. Large ganglionic cell.  
c. Non-ganglionic cell.  
d. Cortical cord.  
e. Chromaffin cells.

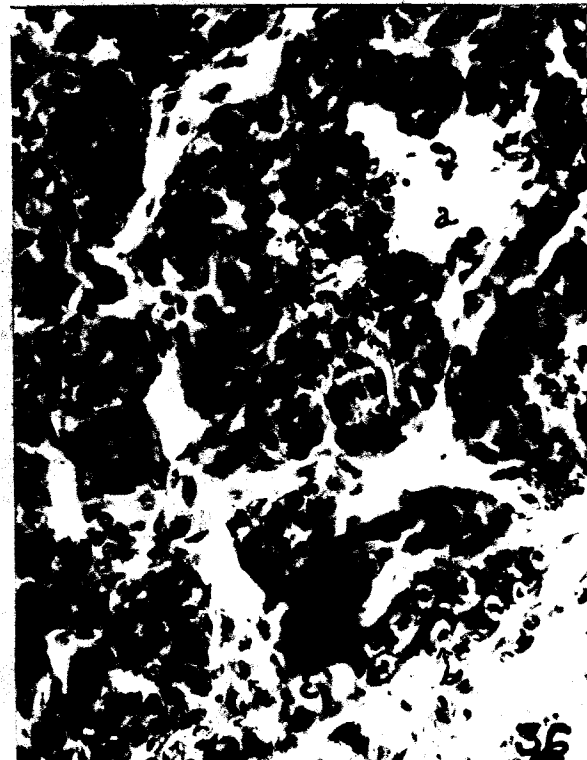
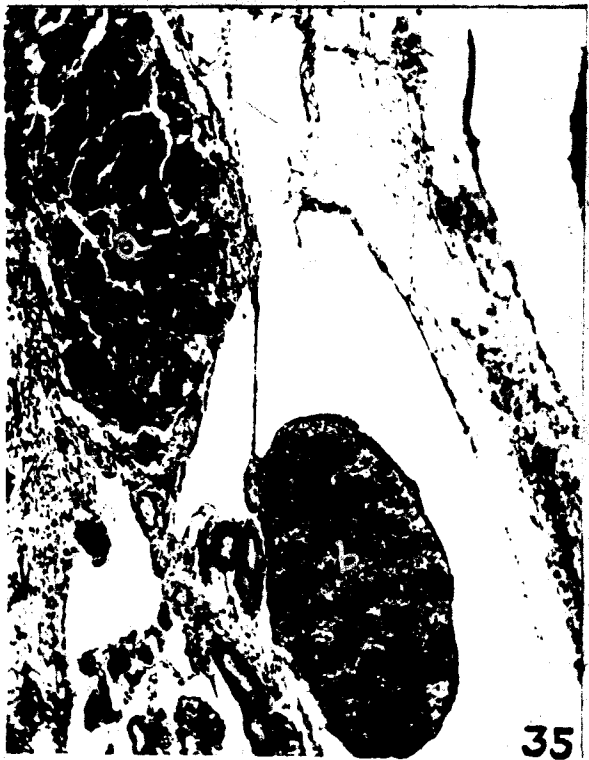

Plate XI

Explanation of figures

Fig. 37. A sagittal section taken from a 284-hour chick embryo showing the relation of the adrenal and the left ovary. Hematoxylin-eosin. 100 X.

- a. Adrenal gland.
- b. Ovarian medulla.
- c. Ovarian cortex.

Fig. 38. A sagittal section of adrenal tissue taken from a 400-hour chick embryo. Iron hematoxylin. 400 X.

- a. Cortical cord.
- b. Chromaffin cells.

Fig. 39. A sagittal section of adrenal tissue taken from a 450-hour chick embryo. Iron hematoxylin. 200 X.

Fig. 40. A transverse section taken through the abdominal cavity of a 120-hour chick embryo showing a portion of the developing gonads. Observe the differences in size and compare the number of primordial germ cells in the left and right gonads. Hematoxylin-eosin. 200 X.

- a. Left gonad.
- b. Right gonad.
- c. Primordial germ cell.

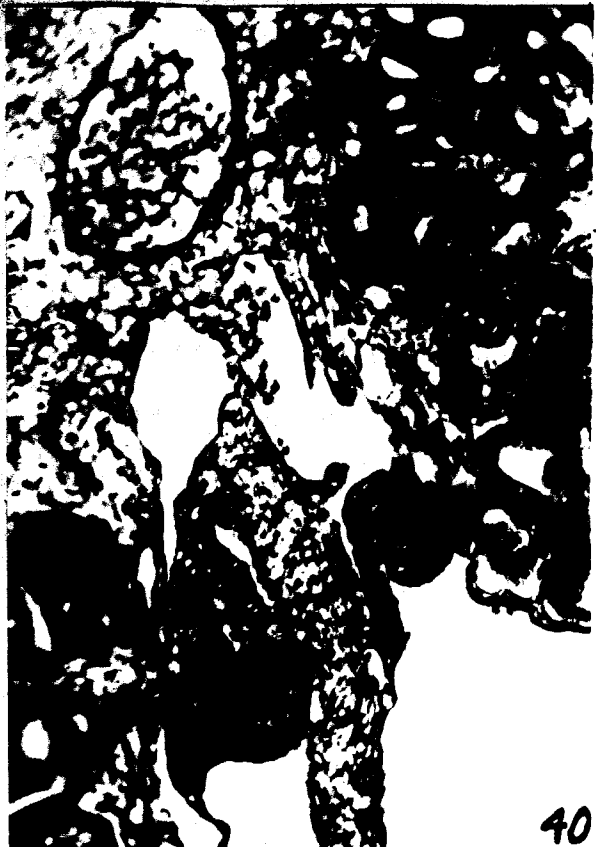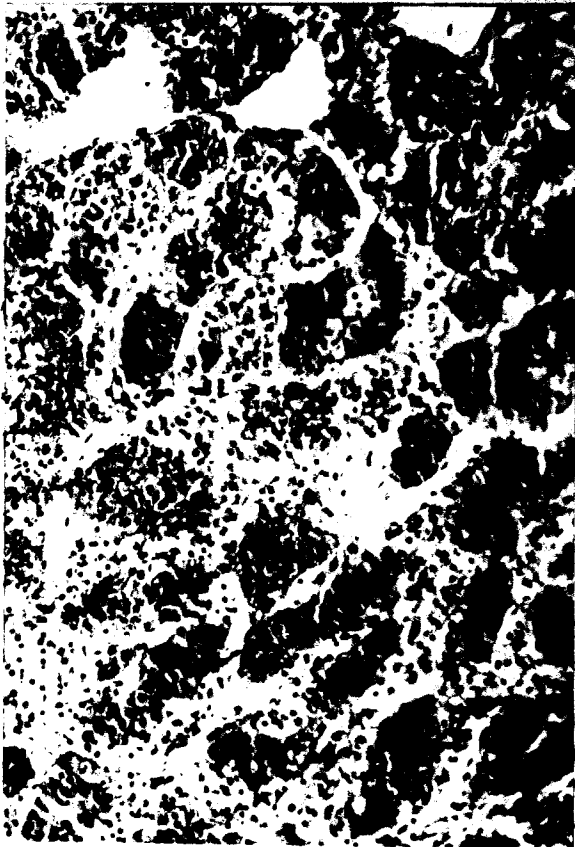


Plate XII

Explanation of figures

Fig. 41. A frontal section taken through the gonads of a 148-hour chick embryo. Hematoxylin-eosin. 200 X.

Fig. 42. A sagittal section taken from the left gonad of a 165-hour female chick embryo. Hematoxylin-eosin. 200 X.

- a. Germinal epithelium.
- b. Shows extent of ingrowth of a primary sex cord from the germinal epithelium.
- c. Primordial germ-cell.

Fig. 43. A sagittal section taken from the testicle of a 165-hour chick embryo. Observe the difference in the thickness of the germinal epithelium between figures 42 and 43. Hematoxylin-eosin. 200 X.

- a. Germinal epithelium only one or two cells in thickness.

Fig. 44. A sagittal section taken from the left ovary of a 213-hour chick embryo. Hematoxylin-eosin. 400 X.

- a. Germinal epithelium.
- b. Primordial germ-cell in a cord of second proliferation from the germinal epithelium.
- c. Primary or medullary tunica albuginea.
- d. Distended medullary cord.
- e. Medullary cord.

Fig. 45. A sagittal section taken from the testis of a 213-hour chick embryo. Hematoxylin-eosin. 200 X.

- a. Germinal epithelium.
- b. Primordial germ-cell in the germinal epithelium.
- c. Primordial germ-cell in the seminiferous cord.

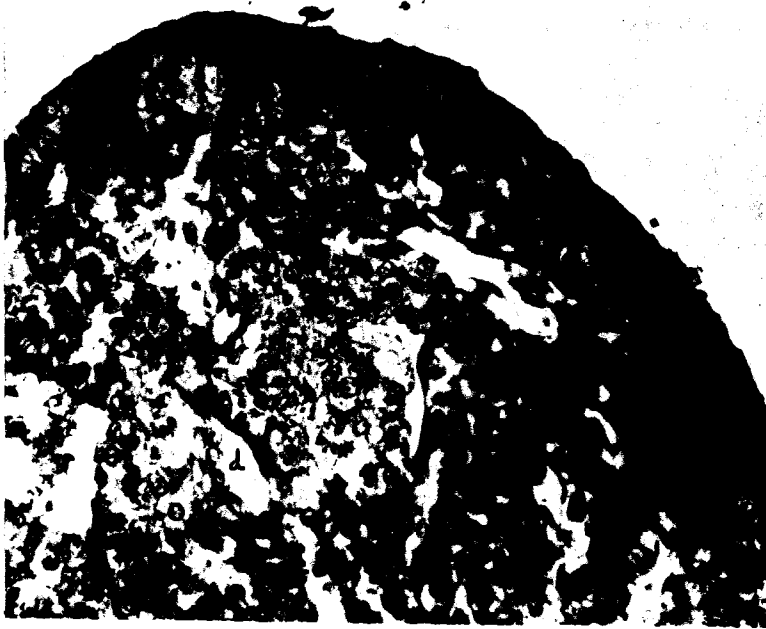
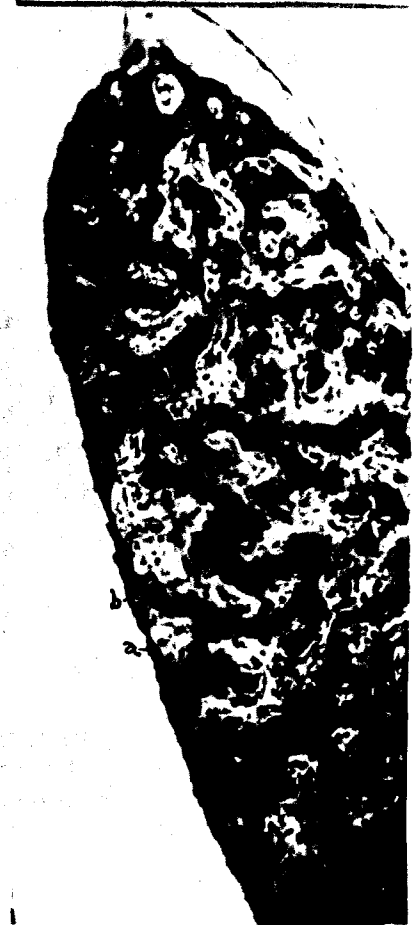
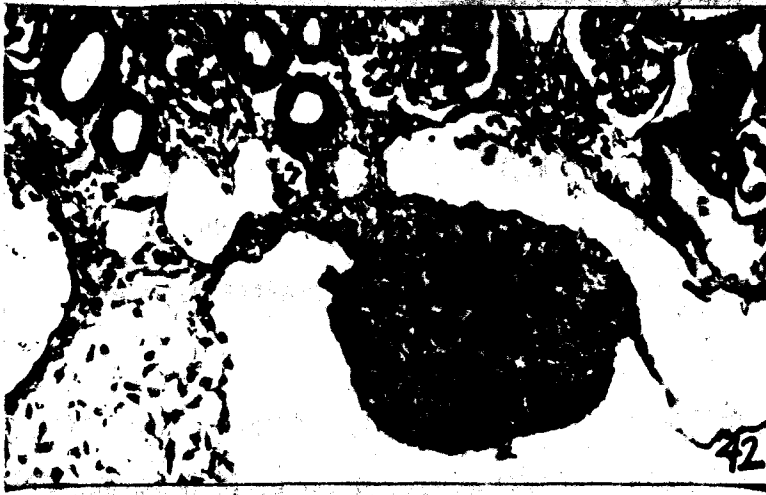
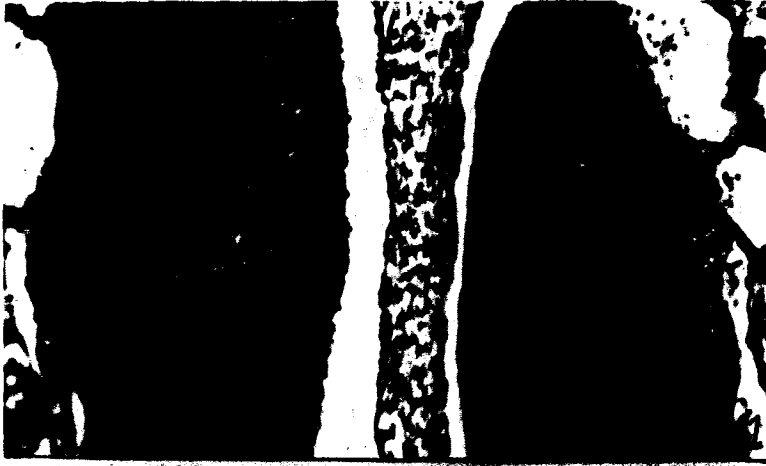Plate XIII

Explanation of figures

Fig. 46. A sagittal section taken from the right ovary of a 240-hour chick embryo. Observe the absence of a cortex and similarity of the gonad to the medulla of the left ovary. Hematoxylin-eosin. 200 X.

- a. Germinal epithelium.
- b. Tunica albuginea.
- c. Distended medullary cord.
- d. Medullary cord.
- e. Primordial germ-cell.

Fig. 47. A sagittal section taken from the left ovary of a 240-hour chick embryo. Hematoxylin-eosin. 400 X.

- a. Germinal epithelium.
- b. Sexual cord of second proliferation.
- c. Distended medullary cord.

Fig. 48. A sagittal section taken from the testis of a 272-hour chick embryo. Hematoxylin-eosin. 100 X.

Fig. 49. A sagittal section taken from the right ovary of a 284-hour chick embryo. Observe its close adherence to the mesonephros. Hematoxylin-eosin. 100 X.

Fig. 50. A sagittal section taken from the left ovary of a 331-hour chick embryo. Observe the well-developed cortex and the single cell layer of germinal epithelium. Hematoxylin-eosin. 400 X.

- a. Germinal epithelium.
- b. Tunica albuginea.
- c. Sexual cord of second proliferation.
- d. Medullary tunica albuginea.
- e. Medullary cord.



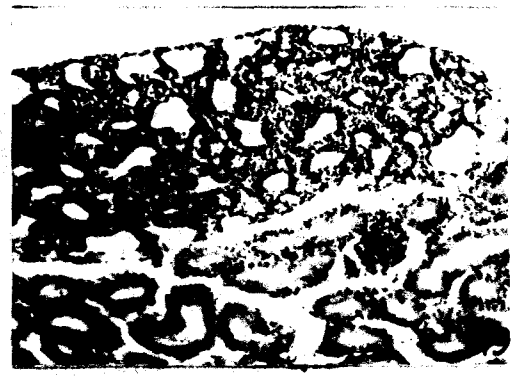




Plate XIV

Explanation of figures

Fig. 51. A sagittal section taken from the left ovary of a 388-hour chick embryo. Hematoxylin-eosin. 200 X.

- a. Germinal epithelium.
- b. Ovarian albuginea.
- c. Cortical cord.
- d. Distended medullary cord.
- e. Medullary tunica albuginea.

Fig. 52. A sagittal section taken from the testis of a 331-hour chick embryo. Hematoxylin-eosin. 400 X.

- a. Germinal epithelium.
- b. Tunica albuginea.
- c. Seminiferous cord.
- d. Germ-cell in seminiferous cord.
- e. Intertubular tissue.

Fig. 53. A sagittal section taken from the left ovary of 498-hour chick embryo. Hematoxylin-eosin. 200 X.

Fig. 54. A sagittal section taken from the testis of a 498-hour chick embryo. Hematoxylin-eosin. 200 A.

